

# ACCURACY OF FINE NEEDLE ASPIRATION CYTOLOGY IN COMPARISON WITH BIOPSY, IN DIAGNOSIS OF PAROTID GLAND NEOPLASM

Sana Salam<sup>1</sup>, Sofia Haider Durrani<sup>1</sup>, Maria Khattak<sup>2</sup>, Hina Shabir<sup>1</sup>, Saimoon<sup>1</sup>, Gulmeena Masood<sup>1</sup>

<sup>1</sup>Oral Pathology, Sardar Begum Dental College, Gandahara University, Peshawar.

<sup>2</sup>Histopathology Deptt, Rehman Medical Institute (RMI), Peshawar.

## ABSTRACT

**Objectives:** To evaluate the accuracy of Fine needle aspiration cytology (FNAC) to be used as a standalone diagnostic tool in parotid gland tumors.

**Materials and Methods:** This prospective study was performed at Rehman Medical Institute, Peshawar. About 49 patients with swellings of the salivary glands were included in the study. FNAC was performed on each of the patient followed by biopsy and the results were compared.

**Results:** Total numbers of benign and malignant lesions were 37 and 12 respectively. In this study the sensitivity of FNAC was 91.7% and specificity was 100%. Positive predictive value was 100% whereas negative predictive value was 97.4%.

**Conclusion:** FNAC was found to be highly accurate in diagnosing the tumors of parotid gland and in differentiating benign and malignant lesions and treatment planning.

**Keywords:** FNAC, parotid gland tumors, sensitivity, specificity.

## INTRODUCTION

A lump in the head and neck is often presented as a diagnostic challenge especially in the salivary gland region since they could be benign malignant or even metastatic.<sup>1,2</sup> Salivary gland masses are potentially neoplastic with cytomorphological heterogeneity and overlapping features.<sup>3</sup> Primary Salivary Gland tumors include a heterogeneous set of 45 morphologic types as described by the World Health Organization (WHO)<sup>4</sup>. These tumors are more common in the parotid glands.<sup>5,6</sup> According to Rahim Dhanani et al, tumors belonging to this region comprise 2 – 6.5% of all head and neck neoplasm and 3% of the entire tumors in the body.<sup>7,8</sup>

FNAC can be used as a primary diagnostic technique in preoperative assessment of parotid gland tumors.<sup>9</sup> FNAC plays an important role in the treat-

ment planning of surgical intervention is necessary and up to which extent it is required.<sup>1,7</sup>

It is a comparatively quick, safe and affordable investigative procedure as compared to biopsy (incisional, excisional, brush), with low morbidity and high diagnostic accuracy.<sup>10-13</sup> Analysis of Layfield et al on the cost efficiency of FNAC in the diagnostic workup of SGL concluded at FNAC reduced the number of unnecessary surgical procedures and overall morbidity along with a 33% reduction in the financial burden.<sup>4</sup> The complications associated with FNAC are minimal as compared to other diagnostic procedures.<sup>11, 14</sup>

This study aims to compare the sensitivity and specificity of FNAC with the morphological analysis of parotid gland swellings and on the basis of that, determine whether FNAC can be used as an adjunct or standalone tool for diagnosis, thus negating the need for a biopsy.

## MATERIALS AND METHODS

This was a cross-sectional comparative study

### Correspondence:

Sana Salam

Senior Lecturer, Sardar Begum Dental College, Peshawar

Email: sanasalamkhattak@gmail.com

Contact: 03139009106

which was carried out in Rehman Medical Institute from August 2017- December 2018. Sample size came out to be 49 by using WHO calculator. Both male and female patients with salivary gland lesions participated in the study and those who already had FNAC done or the aspiration was insufficient were excluded from the study. Patients with parotid gland swellings coming to surgical and outpatient department were selected to go through FNAC by one oral and one histopathologist. 21-25 gauge needle was used for FNAC after taking written consent. The cytological results were then compared with morphological results. All the data was analyzed via statistical package for social sciences SPSS(version 22 software). The p-value was determined using fisher exact test in FNAC. The statistical significance was set at  $P < 0.0005$

**RESULTS**

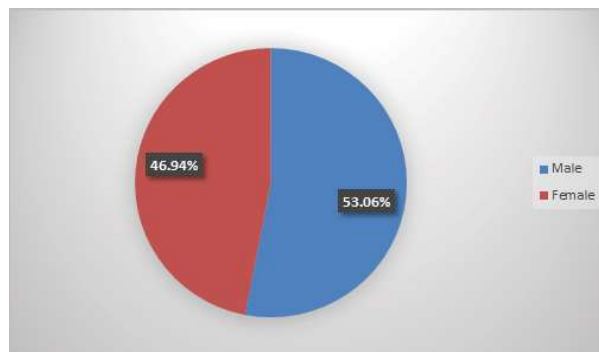
A total number of 49 patients with swellings of the parotid were selected. Gender distribution was slight male predominant with 26 males and 23 females. The participants of the study displayed a mean age of  $44 \pm 7$  years old (mean  $\pm$  standard deviation), with the youngest and oldest patients being 30 and 60 years respectively. The cytological examination of the parotid gland tumors resulted in 75.5% benign and 24.5% malignant cases. There was only one discordant result. The 49 cases were statistically analyzed and a comparison of cytological vs. histopathological was made. The sensitivity was 91.6% whereas the specificity was 100%. Positive and negative predictive values were 100% and 97.4% respectively. None of the severe complications were observed after the FNAC procedure.

**Table no. 1: 2x2 Comparison Table of FNAC and Histopathology results**

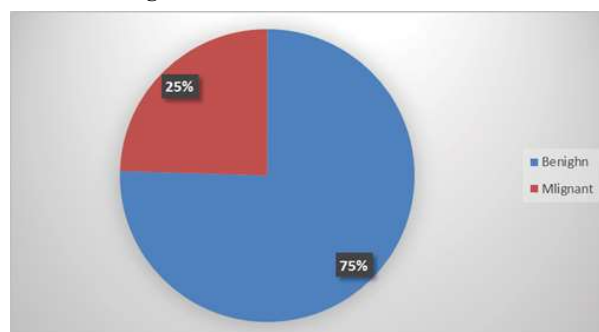
	Malignant proven by FNAC	Benign proven by FNAC
Malignant proven by HP	11	1
Benign proven by HP	0	37

**Table no. 2: Validity Parameters of FNAC**

Sensitivity	91.6%
Specificity	100%
PPV	100%
NPV	97.4%



**Figure 1: Gender distribution chart.**



**Figure 2: Frequency of Benign and Malignant lesions in percentage**

**DISCUSSION**

Salivary gland tumors often presents as a diagnostic challenge in respect to the site of origin and behavior as malignant or benign.<sup>6</sup> Parotid gland is common for these lesions with a small percentage occurring in submandibular, sublingual and minor salivary glands.<sup>14,15</sup> There are different diagnostic modalities for salivary gland lesions that include clinical examination, radiographic examination, cytopathology and biopsy<sup>16</sup>. The deficiency of appropriate clinical or radiological features which provides a significant diagnosis, the usual open biopsy is not mandatory now because of its complications.<sup>17</sup>

FNAC has been recognized as an important diagnostic technique for various lesions of the head and neck region<sup>13,18,19</sup>, and is considered safe in respect to complications.<sup>7,20,21</sup> FNAC can help differentiate between benign and malignant tumors which will further decide the treatment planning.<sup>7</sup>

The FNAC results in this study were categorized as: false-positive (cytological specimen was incorrectly considered or suspect for malignancy), false-negative (cytological specimen failed to diagnose a malignancy), true-positive (presence of malignancy correctly diagnosed), true-negative

(absence of malignancy correctly diagnosed). The histopathological and cytological results were compared and the specificity, sensitivity, negative predictive value (NPV), positive predictive value (PPV) were calculated.

In this study the sensitivity and specificity was 91.6% and 100% respectively. In literature not many variations can be observed. In a study by Shabana Naz et al. sensitivity and specificity were observed to be 85.7% and 98.15%. Whereas Rahim Dhanani and colleagues observed 88.9% and 97.9% sensitivity and specificity. Positive and negative predictive value in this study was 100% and 97.4%.

Parotid tumors have vast histopathological diversity and the bulk is benign.<sup>7</sup> In this study out of 49 cases 37(75.5%) were benign while 12(24.4%) were malignant which correlates with a study done previously in India . Out of the neoplastic parotid swellings 68.2% were benign and 31.85% were malignant.<sup>3</sup> In a study conducted in Egypt 80% of parotid tumors are benign which is also in concordance with our study.<sup>6</sup> In the current study total percentage of malignant cases that were correctly diagnosed was 91.7% and the percentage of benign lesions that were correctly diagnosed was 100%. There was only one case of mucoepidermoid carcinoma that was misdiagnosed as warthin tumor giving a false negative ratio of 8.3%. This is also very similar to a study by Ahmed Youssef et al where one of the discordant results was mucoepidermoid carcinoma cytologically misdiagnosed as warthin tumor with a false negative ratio of 6.8%.<sup>6</sup> Mucoepidermoid carcinoma is a tumor that presents enormous cell heterogeneity. It has numerous degree of atypia. Therefore low-grade lesions may be mistaken for benign lesions and the results are often false negative. In another study conducted by Samreen Naz false negative results was 11.1% in which mucoepidermoid carcinoma was misdiagnosed as pleomorphic adenoma most probably due to the morphological diversity of its epithelial component.<sup>22</sup>

In studies by Youssef and Thulai low levels of sensitivity of FNAC which are 57% and 64% respectively have been reported, even though they included larger number of patients (n=169, n=228). These results are very divergent from our current study with a sensitivity of 91.6%. The most plausible reason for lower levels of sensitivity most probably

can be explained by the fact that in these studies clinicians performed FNAC instead of pathologists.<sup>6,23</sup>

In the current study pleomorphic adenoma is found to be the most frequent tumor comprising more than half of all the tumors i-e 59.2%. Angshuman Dutta and colleagues and Shabana Naz and colleagues also reported in their study, the most common lesion as pleomorphic adenoma which is in agreement with our study.<sup>4,15</sup>

Salivary gland neoplasm can occur at any age. In our study the age range of the patients was 30-60 years with the mean age of 40 years, which correlates with another study conducted by Rahim Dhanani et al on 290 patients, where the average age was 48.2 years.<sup>7,24</sup>

In our study we observed male predominance with 26(53.06%) males and 23(46.94%) females which correlates with a study carried out by Shabana Naz et al, which had 64.6% males and 35.4% females however the results of previous studies show variations in gender predilection.<sup>4</sup>

The present study has focused on whether FNAC is useful in clinical management of parotid gland tumors or not. This study has manifested set of conditions in which FNAC may be useful and valuable. Surgical management for neoplastic tumors is also advised but recognition of benign lesions before surgery is also of great help in planning the extent of surgery which is possible with FNAC. It will also help clinician to counsel the patient about prognosis of the disease.

## CONCLUSION

FNAC is expected to influence the management of the patient where the clinical features suggest the likelihood of a tumor whether benign or malignant. FNAC is a quick, simple and effective diagnostic technique for neoplastic lesions. It is technically an easier procedure than the open biopsy. In these situations FNAC can make it promising to choose conservative management.

## REFERENCES

1. Sam T. H. Reerds MD, Adriana C. H. Van Engen-Van Grunsven MD P, Frank J. A. van den Hoogen MD P, Robert P. Takes MD P, Henri A. M. Marres MD P, Jimmie Honings MD P. Accuracy of parotid gland FNA cytology and reliability of the Milan System for Reporting Salivary Gland Cytopathology in clinical practice.

- cancer cytopathology. 2021;1:29(9):719-28.
2. Hanege FM, Tuysuz O, Sakallioğlu O, Solmaz OA. Diagnostic value of preoperative fine needle aspiration cytology in parotid gland tumors. *diagnostic cytopathology*. 2020;48(11):1075-80.
  3. Das P, DasNayak G, Pandey N, Dash K. Utility of FNAC in salivary gland swellings with clinico-histological correlation in a tertiary care hospital. *IP journal of diagnostic pathology and oncology*. 2020;5(2):157-62.
  4. Naz S, AbdurRehman, Naeem S, Ali F, Ali K, Maqbool S, et al. Diagnostic precision of fnac for salivary gland lesions. *journal of khyber college of dentistry*. 2020;10:59-66.
  5. Lanišnik B, Levart P, Čizmarevič B, Švagan M. Surgeon-performed ultrasound with fine-needle aspiration biopsy for the diagnosis of parotid gland tumors. *journal of the sciences and the specialities of head and neck* 2021;43(6):1739-46.
  6. Youssef A, Cope D, Alsedra S, Zahran M, Tahan ARE. Role of FNAC in diagnosis of parotid lesions. *The Egyptian Journal of Otolaryngology* volume. 2021;37(47):2-4.
  7. Dhanani R, Iftikhar H, Awan MS, Zahid N, Momin SNA. Role of Fine Needle Aspiration Cytology in the Diagnosis of Parotid Gland Tumors: Analysis of 193 Cases. *Int Arch Otorhinolaryngol*. 2020;24(4):508-12.
  8. Poudel A, Shrestha B, Regmi S. Evaluation of Salivary Gland Lesions by Fine Needle Aspiration Cytology at a Tertiary Care Hospital, Western Nepal. *Pathology and Laboratory Medicine International* 2020;12:9-17.
  9. Chrabańska M, Kiczmer P, Drozdowska B. Salivary gland lesions: diagnostic reliability and challenges of fine needle aspiration cytology. *international journal of clinical and experimental pathology*. 2021;14(1):54-62.
  10. Zahran M, Alsedra S, Cope D, Youssef A. The Role of FNAC in the Diagnosis and Management of Warthin Tumour: Analysis of 74 Cases. *International Archives of Otorhinolaryngol*. 2020(02).
  11. Katta R, Chaganti DP. Application of the Milan system of reporting salivary cytopathology – A retrospective cytohistological correlation study. *journal of Dr NTR university of health sciences*. 2019;8(1):11-7.
  12. Mukundapai M, Sharma N, Patil A, Gopal C. Fine-Needle Aspiration Cytology of Salivary Gland Lesions: A Revised Classification Based on “Milan System”—4years Experience of Tertiary Care Cancer Center of South India. *journal of cytology*. 2020;37(1):12-7.
  13. Fazilet Altin, Yalcin Alimoglu, Acikalin RM, Husamettin Yasar. Is fine needle aspiration biopsy reliable in the diagnosis of parotid tumors? Comparison of preoperative and postoperative results and the factors affecting accuracy. *Brazilian Journal of Otorhinolaryngology*. 2019;85(3):257-81.
  14. Khandelia R. Fine needle aspiration cytology in diagnosis of salivary gland lesions. *International Journal of Scientific Research* 2017;6(8).
  15. Dutta A, Bhat S, Dutta D, Sharma P, Gianch S. Study and correlation of clinical, cytological and histopathological findings in diagnosis of parotid gland masses. *International Journal of Otorhinolaryngology and Head and Neck Surgery* 2019;5(2):427-9.
  16. Rammeh S, Romdhane E, Sassi A, Belhajkacem L, Blel A, Ksentini M, et al. Accuracy of fine-needle aspiration cytology of head and neck masses. *Diagn Cytopathology*. 2019;47(5):394-9.
  17. López-Pazos P, Pérez-Sayáns M, Chamorro-Petronacci C, Suárez-Peñaranda JM, Xabier M-M, Torreira MG, et al. Fine-needle aspiration cytology-efficacy in pre-surgical diagnosis of salivary gland tumors. *Biomedical Research*. 2018;29(13).
  18. Howard H. Wu, Alruwaili F, Zeng B-R, Cramer HM, Lai C-R, Hang J-F. Application of the Milan System for Reporting Salivary Gland Cytopathology A Retrospective 12-Year Bi-institutional Study. *American Journal of Clinical Pathology J clinpathol*. 2019;151:13-21.
  19. Rossi ED, Wong LQ, Bizzarro T, Petrone G, Mule A, Fadda G, et al. The Impact of FNAC in the Management of Salivary Gland Lesions: Institutional Experiences Leading to a Risk-Based Classification Scheme. *cancer cytopathology*. 2016;124(6):388-96.
  20. Sikdar N, Sriram V, Ivan EA. Cytological and Histopathological Correlation of Salivary Gland Lesions. *journal of medical science and clinical research*. 2018;06(7).
  21. Singh S, Singh P, Auplish R, Khanna SP, Verma K, Aulakh SK. Application of Milan system for reporting of salivary gland pathology and risk stratification: An institutional experience. *journal of oral and maxillofacial pathology*. 2020;24.
  22. Naz S, Hashmi AA, khurshid A, Faridi N, Edhi MM, Kamal A, et al. Diagnostic role of fine needle aspiration cytology (FNAC) in the evaluation of salivary gland swelling: an institutional experience. *biomed central research notes*. 2015;8(101):2-5.
  23. Al-thulaia HAM, Mohamed EA, Almobarak AO. Fine Needle Aspiration Cytology as a Diagnostic Tool in Parotid Swellings Among Patients Attending Khartoum Teaching Dental Hospital. *Clinical Medicine Journal*. 2016;2:6-12.
  24. Pal S, Mondal S, Bose K, Pradhan R, Bandyapadhyay A, Bhattacharyya D. Fine needle aspiration cytology of minor salivary gland tumors: A retrospective 5-year study of 42 cases in a tertiary care hospital. *Journal of cancer research and therapeutics*. 2019;15(3):686-9.