

DIFFERENCES IN INCLINATION OF CRANIOFACIAL REFERENCE PLANES TO TRUE HORIZONTAL LINE-A CROSS-SECTIONAL STUDY

Muhammad Saood¹, Muhammad Asim², Nasir Mushtaq³, Akbar Ali Khan⁴, Imran Tajik⁵

¹ Department of Orthodontic, Khyber College of Dentistry, Peshawar.

² Department of Orthodontic, Bacha Khan Dental College, Mardan.

³ Department of Orthodontic, Rehman College of Dentistry, Peshawar

⁴ Department, KMU Institute of Dental Sciences Kohat.

⁵ Department of Orthodontic, Sardar Begum Dental College, Peshawar

Abstract

Objectives: The aim of the present study was to evaluate the relation of Craniofacial reference planes of Frankfort horizontal plane (FHP) and the Sella Nasion (SN) plane to a True horizontal line (THL).

Materials & Methods: A cross sectional descriptive study using a prospective consecutive sampling technique was designed. Lateral Cephalograms of 59 patients were recorded over a period of 3 months by X-Caliber CM (Asahi Roentgen Ind. Co, Japan) in a standing mirror-guided NHP. Physically and mentally healthy patients willing to undergo orthodontic treatment, in adult dentition stage and without any syndromes were included. SPSS version 20 was used to calculate the descriptive statistics and means difference of craniofacial reference planes to the THL.

Results: The FHP and SN plane showed an angular variation of 2.34 ± 4.13 and 10.42 ± 4.70 degrees respectively, with respect to THL. The SN plane showed an anterior upward inclination of 8.08 ± 3.58 degrees to FHP.

Conclusion: Both FHP and SN planes showed significant variation to THL. So FHP and SN planes should be used with caution as they can mislead our diagnosis of the problem and ultimately the treatment planning.

Key Words: Frankfort horizontal plane, Cephalometry, Natural Head Position.

Introduction

An ideal reference plane in cephalometric analyses must have good stability, reproducibility, reliability and minimal inter individual variability. It should also precisely represent the body in the respective plane¹.

In cephalometric analyses, horizontal reference

planes are used to determine the skeletal discrepancies in the anteroposterior plane. They can be broadly divided into intra-cranial and extra-cranial reference planes²⁻⁴. Frankfort horizontal plane (FHP) and Sella-Nasion (SN) plane are two widely used intra-cranial reference planes⁵. However, intra-cranial reference planes are subject to change during growth and vary significantly among individuals^{6,7}. Downs demonstrated cant of the FHP in three different persons with a nearly same facial profile, resulting in different cephalometric facial typing⁸. Bjork, in his classical paper, also reported similar discrepancies in two Bantus with an almost similar profile but remarkable variation in the inclination of cranial base⁹. FHP has also low reliability because

Correspondence:

Muhammad Saood

Assistant Professor,
Orthodontic Department, Khyber College of Dentistry,
Peshawar

Cell # 0333 9155820

E-mail: saudroomi9@gmail.com

both of its landmarks(Porion, Orbitale) are often difficult to trace¹.

Natural head posture has been proposed as an extra cranial reference plane for cephalometric analysis since the 1950s. It is a standardized position of the head in an upright head posture with one's eyes focused on a point in a distance at eye level¹⁰⁻¹².

Numerous Studies have shown that NHP is reproducible and stable, both in short- and long-term intervals¹³⁻¹⁶. The true horizontal line is constructed by drawing a perpendicular to the plumb line, which is used as a true vertical reference line before taking a photograph/radiograph in NHP⁶.

Due to the factors mentioned above, a critical and systematic assessment of the reliability of FHP and SN plane is necessary. The true Horizontal line is a stable, reliable and reproducible plane and both FHP and SN plane inclination can be compared with it. Therefore, this study aims to evaluate the variability of FHP and SN plane about the True horizontal line. Both FHP and SN plane is part of the contemporary cephalometric analyses, so any variation in their inclination can mislead our diagnosis of the problem and ultimately the treatment planning.

Materials and Methods

The cross-sectional study used good quality Lateral cephalograms of 59 participants which were prospectively selected using consecutive sampling technique over a period of 3 months. The Cephalograms were a part of the pre-treatment records of patients attending the Orthodontic Department, Sardar Begum Dental Hospital, Peshawar. Participants in the adult dentition stage (13 years and beyond) and without any mental or physical illness were included. Those with any craniofacial syndromes were excluded.

All radiographs were recorded by X-Caliber CM (Asahi Roentgen Ind. Co, Japan) in a standing mirror-guided NHP using a protocol based on the method of Solow and Tallgren.¹⁷ This involved each subject performing a series of neck-bending exercises and, while looking into their eyes, walking into a position approximately 1 meter away from a 2×3 feet wall-mounted mirror. A freely hanging metal chain in front of each subject's profile defined the true vertical. Each participant was instructed to swallow and then keep their teeth lightly closed together, at

which point a lateral cephalograph was obtained with standardized cephalometric equipment.

Each lateral cephalograph was then manually traced on acetate paper, by the same observer (MA). To produce a tracing orientated in NHP, the true vertical plumb line was traced. A true horizontal line (THL) was then constructed perpendicular to the vertical plumb line of each tracing. FHP and SN plane were traced, and their angulations with THL were recorded.

Descriptive statistics including the mean, standard deviation, maximum, and minimum for each variable were calculated using SPSS version 20 software. Inter-examiner and intra-examiner reliability were checked using the Cronbach's alpha by re-measuring angles by the same investigator (MA) and by another investigator(SS), respectively, after one month. Student test was used to compare the mean difference of FHP and SN plane angulation with THL. Ethical approval for the present investigation was obtained from the Ethical Committee of Gandhara University, Peshawar.

Results

A total of 59 individuals (39 females, 20 males) were included in this study with a mean age of 17.91 + 4 years. Good inter and intra examiner reliability was observed for readings ($r > 0.95$).

Both FHP and SN plane inclination vary considerably with respect to the true Horizontal line. Student t-test showed significant difference FHP to THL was 2.34+4.13 degrees ($p < 0.05$), with a wide range of -13 to +11 degrees. Both planes were parallel in only 8.4% of patients ($p > 0.05$). Statistically significant difference between SN plane to the true horizontal line was found with a mean difference of 10.42+4.70 degrees ($p < 0.05$) and range of -2 to +22 degrees. Significant angle difference of 8.08+3.58 degrees ($p < 0.05$) was also found between FHP and SN plane.

Discussion

Frankfort horizontal is most commonly used as it is a reference plane that useful for the description or classification, as in facial typing, for super imposition of radiographic cephalograms and may involve growth and treatment changes and add in treatment planning. We found statistically significant differences between Frankfort horizontal as compared to

Fig: 1 Gender distribution of the sample

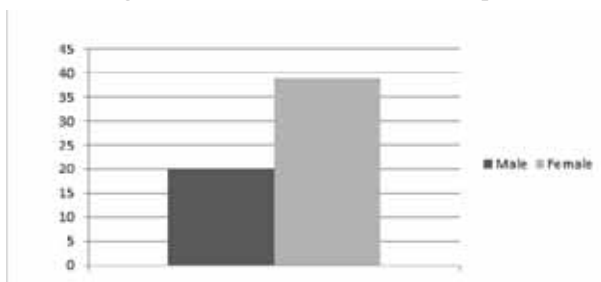


Fig: 2 scatter plot showing distribution of sella nasion plane with respect to true horizontal line

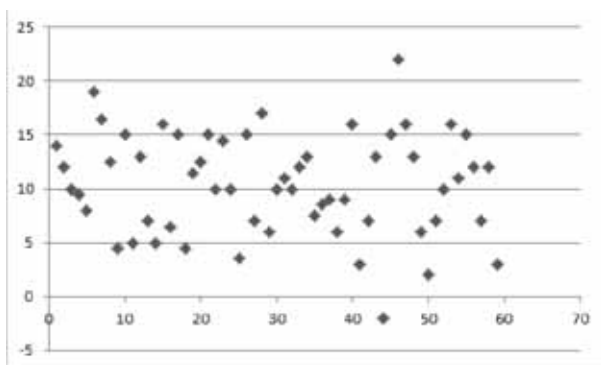
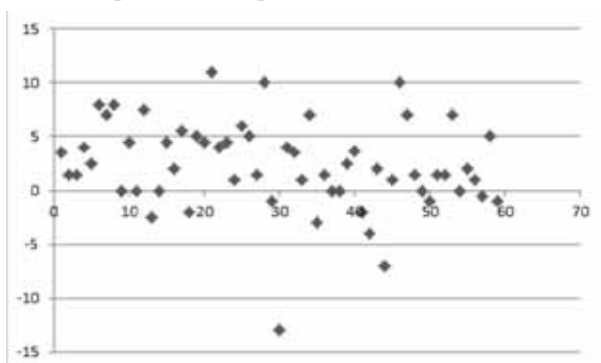


Fig: 3 Scatter plot showing distribution of frankfort horizontal plane with respect to the true horizontal line



the true horizontal line. This could be attributed to the difficulty in accurately determining portion point. Also, the natural head position is affected by mode of respiration, facial features and general posture of the patient which could lead to differences in aligning the natural head position to true horizontal²¹.

Downs⁸ introduced Frankfort horizontal into a well-organized cephalometric analysis by using the angle of the facial plane (N-Pog) to Frankfort horizontal to classify facial types. However, he noted disagreement in the cephalometric and clinical findings in some patients. By using photographs of 100 patients taken in natural head position, he found

Frankfort plane (upper margin of the soft-tissue ear canal to orbitale, marked after palpation) to have a mean upward tip anteriorly of $1.3+5.0$ degrees.⁸ This difference is less than that in our study ($2.34+4.13$ degrees), which may be due to different methodologies and different Frankfort planes used in both studies. This study used Hard tissue FHP instead of Downs Soft tissue FHP traced to photographs.

Moorrees¹⁷ in his study found Frankfort to be about 92 degrees to true vertical opening postero-inferiorly (Or 2 degree anteriorly upward to the true horizontal line), with a standard deviation of about +4 degrees. He concluded that natural head position with true vertical as an extra-cranial reference line is more reliable than intra-cranial reference planes. This finding is consistent with our study which also shows an anterior upward inclination of FHP. Marcotte¹⁸ constructed true horizontal by drawing a plane 7 degree anteriorly down to SN plane, which he proposed to be fairly close to anatomical FHP. This value is also close to that observed in our study ($8.08+3.58$ degrees).

In our study, NHP is used as a standard reference plane. It is an individual functional physiologic position that has been used in anthropological studies for centuries and is recognized as a good reference for cephalometric analyses in orthodontics. Several types of research showed good stability and Reproducibility of NHP both short and long time intervals. Cooke¹⁹ in his longitudinal study showed a good stability of NHP over 15 years of the observational period. However, NHP can be influence by many factors, for example, different postures and methods²⁰. It has been observed clinically that when ear rods from the cephalostat are plugged in patient's ears, they tend to hold their head in an unnaturally extended or lexed position when radiographs are taken, which would give misleading outcomes²⁰. Therefore, in our study, the patient's head was left unsupported in cephalostat, without inserting the ear rods.

Both FHP and SNP showed significant variation with a large inter-individual variation. As these planes are an integral part of our cephalometric analysis, they can mislead our diagnosis and can ultimately affect our treatment plan. One should take caution while making a diagnosis solely based on these planes. Relationship of the jaws should be

assessed with multiple planes, to minimize error in the diagnosis of the actual discrepancy.

Conclusion

1. The FHP and SN plane show a significant variation of 2.34±4.13 and 10.42±4.70 degrees respectively, with respect to THL. These difference were statistically significant.
2. Both FHP and SN planes can mislead our diagnosis of the problem and ultimately the treatment planning so that they can be used with caution.

References

1. David P. Madison, Wayne J. Sampson, Grant G. Townsend. Craniofacial reference plane variation and natural head position. *Eur J Orthod.* 2008;30(5):532-540.
2. Cooke MS, Wei SH. A summary five-factor cephalometric analysis based on natural head posture and the true horizontal. *Am J Orthod Dentofacial Orthop.* 1988;93:213–223.
3. Cooke MS, Wei SH. The reproducibility of natural head posture: a methodological study. *Am J Orthod Dentofacial Orthop.* 1988;93:280–288.
4. Lundstrom A, Lundstrom F, Lebrecht LM, Moorrees CF. Natural head position and natural head orientation: basic considerations in cephalometric analysis and research. *Eur J Orthod.* 1995;17:111–120.
5. Moorrees CF. [Cephalometry and orthodontics after the introduction of Van Loon's "cubuscranioforus"]. *Ned Tijdschr Tandheelkd.* 1988;95:461–467.
6. Dima P. Dvortsina, Qingsong Yeb, Gerard J. Pruimc, Pieter U. Dijkstrad, Yijin Rene. Reliability of the integrated radiograph-photograph method to obtain natural head position in cephalometric diagnosis. *Angle Orthod.* 2011;81:889–894.
7. Houston WJ. Bases for the analysis of cephalometric radiographs: intra cranial reference structures or natural head position. *Proc Finn Dent Soc.* 1991;87:43–49.
8. Downs WB. Analysis of the dentofacial profile. *Angle Orthod.* 1956;26:192–299.
9. Bjork A. Some biological aspects of prognathism and occlusion of the teeth. *Angle Orthod.* 1951;21:3–27.
10. Moorrees CFA. Natural head position—a revival. *Am J Orthod Dentofacial Orthop.* 1994;105:512–513.
11. Moorrees CFA. Natural head position: the key to cephalometry. In: Jacobson A. ed. *Radiographic Cephalometry: From Basics to Video imaging.* Chicago, Ill: Quintessence; 1995:175–184.
12. Moorrees CF. Growth and development in orthodontics. *Curr Opin Dent.* 1991;1:609–621.
13. Cooke MS. Five-year reproducibility of natural head posture: a longitudinal study. *Am J Orthod Dentofacial Orthop.* 1990;97:489–494.
14. Peng L, Cooke MS. Fifteen-year reproducibility of natural head posture: a longitudinal study. *Am J Orthod Dentofacial Orthop.* 1999;116:82–85.
15. Lundstrom A, Forsber CM, Westergren H, Lundström F. A comparison between estimated and registered natural head posture. *Eur J Orthod.* 1991;13:59–64.
16. Lundstrom F, Lundstrom A. Natural head posture as a basis for cephalometric analysis. *Am J Orthop.* 1992;101:244–247.
17. Solow B, Tallgren A. Natural head position in standing subjects. *Acta Odontologica Scandinavica* 1971;29:591–607.
18. Marcotte M. Head posture and dentofacial proportions. *Angle orthod.* 1981;51:208–13.
19. Jianga J, Xub T, Linc X. The Relationship Between Estimated and Registered Natural Head Position. *Angle Orthod.* 2007;77:1019–24.
20. Dvortsin DP, Ye Q, Pruim GJ, Dijkstra P, Ren Y. Reliability of the integrated radiograph-photograph method to obtain natural head position in cephalometric diagnosis. *Angle Orthod.* 2011;81:889–894.
21. Solow B, Tallgren A. Head posture and craniofacial morphology. *Am J Phys Anthropol.* 1976;44:417–436.