

USE OF BUCCAL ADVANCEMENT FLAP FOR REPAIR OF OROANTRAL FISTULA: A CASE SERIES STUDY

Malik Ali Hassan Sajid¹, Salman Ashraf², Uzair Bin Akhtar³, Usman Ul Haq⁴, Saif Ullah⁵, Khushal Bimb⁶

¹Department of Oral and Maxillofacial Surgery, FMH College of Medicine & Dentistry, Lahore

²Department of Oral and Maxillofacial Surgery, Quid-e-Azam Medical College/Bahawal Victoria Hospital, Bahawal Pur.

³Department of Oral and Maxillofacial Surgery, Sharif Medical & Dental College, Lahore.

⁴Department of Oral and Maxillofacial Surgery, HITEC-IMS Dental College, Taxila Cantt.

⁵Department of Oral and Maxillofacial Surgery, Bacha Khan Medical College, Mardan.

⁶Department of Oral and Maxillofacial Surgery, Nepal Medical College-College of Dental Sciences & Hospital Gokarneshwor Municipality Attarkhel Kathmandu.

ABSTRACT

Objective: To evaluate the success rate of Buccal advancement Flap (BAF) in closure of Oroantral communication (OAC) and Fistula.

Materials and Methods: In this case-series study, buccal advancement flap (BAF) was used in 45 consecutive patients at Oral and Maxillofacial Surgery Department of Fatima Memorial Hospital Lahore for period of one year (May 2018-May 2019). Male to female ratio was 2:1 and mean age=26 years. Right maxillary OAF of first and second molars presented more than left side (n=35, 77%). All defects were not more than 5mm. After application of flap, patients were evaluated for sign and symptoms of infection, wound dehiscence, loss of flap whether partial or complete and recurrence of oroantral fistula (OAF). Data was analyzed using SPSS version 20, INC, Chicago USA with descriptive analysis to derive percentages and frequencies for all variables.

Results: Thirty nine patients (86%) had successful healing of flap. Partial loss occurred in one patient (2.25%). Wound dehiscence was seen in two patients (4.45%). Complete loss of flap was also noted in two patients (4.45%). Recurrent OAF has occurred in one patient (2.25%).

Conclusion: BAF is a flap of choice for immediate closure of OAC and OAF of ≤ 5 mm in the region of maxillary first and second molar. The technique is simple and vascular supply ensures the proper healing of flap. More work needs to be done to evaluate the causes for the partial or complete loss of the flap.

Keywords: Oroantral Communication (OAC), Oroantral fistula (OAF), Buccal advancement flap (BAF).

INTRODUCTION

The communication between maxillary sinus and oral cavity is called oroantral communication (OAC). If not treated it becomes lined with epithelial lining

hence called oroantral fistula (OAF).^{1,2} Most common cause for oroantral fistula is exodontia (48%), while extracting first or second maxillary molars.³ Other causes are tumors (18%), osteomyelitis (11%), Caldwell luc procedure (8%), trauma (7.5%), cyst (3.7%) and septal perforation (3%).^{4,5} Males are more affected during third decade of life while extracting first maxillary molars.⁶ If oroantral communication is left untreated patient develops sign and symptoms of purulent discharge from fistulous tract, regurgita-

Correspondence:

Dr. Malik Ali Hassan Sajid

B.Sc., BDS, FCPS (OMFS), MHPE (Med Edu)

Associate Professor, Department of Oral and Maxillofacial Surgery, FMH College of Medicine & Dentistry, Lahore.

Email: : draliz14@yahoo.com

Contact: +92300-4469598

tion of oral fluids through nose, hyper-resonance of speech and/or chronic sinusitis.^{5,6}

Elimination of infection, excision of fistulous tract and proper post-operative care is the treatment protocol for oroantral fistula.^{7,8} Also according to literature, any communication between maxillary sinus and oral cavity more than three weeks should be closed surgically.⁹ Although immediate closure has 95% success rate.⁹

Another protocol being followed for any defect less than 5mm closes spontaneously. However, more than 5mm communication needs surgical closure. 1, 10 Some of traditional methods being employed for OAC/OAF are buccal advancement flap, palatal rotational flap, buccal fat pad flap, nasolabial flap and tongue flap.^{11,12} Moreover double or triple-layered techniques, plasma-rich fibrin membrane, auricular cartilage and other surgical options have also been employed with variable success.^{20, 22, 23}

Most common surgical procedure used for the repair of oroantral fistula is buccal advancement flap which is a trapezoidal flap that is sutured over the defect. Broad base of this flap ensures the good vascularity to this flap.^{13, 14} It can have upto 93% success rate and an advantage to be performed under local anesthesia. Only disadvantage to this technique is somewhat obliteration of gingival buccal sulcus which may create difficulty for prosthesis in future.^{15, 16} This method can also be combined with palatal rotational flap, buccal fat pad flap and/or with other combinations.^{16, 18, 19, 21}

This study was also carried out to compare and assess the success rate with the application of buccal advancement flap in immediate and delayed closure of oroantral communication (OAC) &/or oroantral fistula (OAF) as it is first choice to be considered in many research studies.

MATERIALS AND METHODS

A study was conducted on 45 consecutive patients from May 2018-May2019 at Oral and Maxillofacial department of Fatima Memorial Hospital Lahore. Majority of patients diagnosed with oroantral fistula were males with M: F ratio of 2:1 (Fig I). The age ranges from 16-55 years with mean of 26+/- 10 years. Right maxillary oroantral fistula of first and second molars presented more than left side (n=35, 77%) (Table 1). A written ethical approval

was obtained from concerned institutional review board (IRB). Patients fulfilling the inclusion criteria with sign and symptoms of oroantral fistula (nasal regurgitation, bubbling with nose-blow test, hyper-resonance in speech), intra oral examination with silver probe through fistulous tract and radiographic examination (periapical, Orthopantomogram, and paranasal sinus view), were included in this study. Those patients having chronic sinusitis with oroantral fistula were excluded. The patients with oroantral fistula who were primarily treated with buccal advancement flap and presented with recurrent oroantral fistula were also excluded from the study. Acute sinusitis was treated with 1 gram amoxicillin/clavulanic acid twice daily for 10-14 days. Written informed consent was obtained from all patients. Same surgeon operated all patients who underwent repair with buccal advancement flap (BAF) under local anesthesia (LA-Lignocaine with epinephrine 1; 100000 ratio).

Surgical Technique: The incision started around fistulous communication at a distance of 3mm and extended in buccal sulcus. Periosteum was scored parallel to base of flap to allow great mobilization of flap. Alveolar height was reduced. Fistulous tract was completely excised. The flap was mobilized over the defect and sutured with 3/0 silk suture. Post-operative instructions were given to the patients to avoid nose blowing, sneezing, tongue touching and tooth brushing. Nasal decongestants and analgesics were prescribed accordingly. Follow up was scheduled on second post op day; weekly, second week, third and fourth weeks. After application of flap, patients were evaluated for sign and symptoms of infection, wound dehiscence, loss of flap whether partial or complete and recurrence of fistula.

Data was analyzed by descriptive statistics (mean SD± deviation). Frequency was calculated for age and gender. Percentages were calculated for all variables (site, rate of success, and closure of fistulous tract, wound dehiscence, flap loss (partial and complete)).

RESULTS

Thirty nine patients (86%) had successful healing of flap. Partial loss has occurred in one patient (2.25%). Wound dehiscence was seen in two patients (4.45%). Complete loss of flap was also seen in two patients (4.45%). Recurrent oroantral fistula occurred

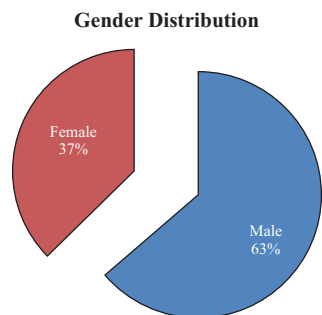


Fig 1: Gender Distribution

Table: 1 Distribution of Extraction Site, oroantral communication (OAC) &/or oroantral fistula (OAF) OAC/OAF

Site and Distribution of OAC/OAF	No. of patients(N)	Percentage (%)
Right side	35	77.78%
First Molar	25	54%
Second Molar	10	23%
Left side	10	22.22%
First Molar	7	15.55%
Second Molar	3	6.67%

Table: 2 Outcome of buccal advancement flap (BAF) Procedure

Successful flap healing	Partial flap loss	Complete flap loss	Wound dehiscence	Recurrent Fistula
n=39,87%	n=1,2.25%	n=2,4.45%	n=2,4.45%	n=1,2.25%

in one patient (2.25%) (Table 2).

DISCUSSION

Exodontias is one of most common causes for occurrence (48%) of oroantral communication (OAC) &/or oroantral fistula (OAF) according to Abuabara⁸ and Klara⁹ and it correlates well with findings of the current study.

As a classical cascade, extraction of maxillary first molar create oroantral communication, if left untreated it is likely to become chronic and an established oroantral fistula. Therefore all patients with immediate oroantral communication after extraction and those having oroantral fistula were selected for application of buccal advancement flap. The studies done by Suckler⁹ and Quershi¹ has also applied buccal advancement flap for oroantral communication (OAC) &/or oroantral fistula (OAF)

to assess the success rate of this flap. The study of Cankaya & his colleagues tested the reliability of buccal advancement flap and palatal rotation flap for oroantral communication (OAC) &/or oroantral fistula (OAF) without chronic sinusitis. In this study the flap was harvested for oroantral communication (OAC) &/or oroantral fistula (OAF) of <5mm and majority of them were male.¹⁵ Meirelles and Dym has also treated male patients with OAC/OAF. Almost same experience was shared by Delgado² who reported male to female ratio as 1.4:1.^{10,11} The findings of the current study are well in line with the above-mentioned studies.

Buccal advancement flap is flap of choice for the closure of oroantral communication &/or oroantral fistula ≤5mm in the study of Borgonova et al,¹² but the study of other authors^{10,15} has tested the reliability of two methods (buccal advancement flap Vs Palatal rotation flap) for the defect measuring ≤5mm. They found 95 % success rate with buccal advancement flap for less than 5mm defect and palatal rotation flap for defects ≥5mm. This study also used buccal advancement flap for <5mm oroantral communication &/or oroantral fistula and found more than 86 % success rate. Palatal rotation flap was used in case of partial (2.25%) or complete loss (4.45%) of buccal advancement flap. Complete loss of flap might have occurred due to chronic sinusitis in the study of Borgonova et al.¹² While in the present study during follow ups, no sign and symptoms of sinusitis were noted while all cases with oroantral communication &/or oroantral fistula with chronic sinusitis were already excluded from this study. The reason for complete flap loss could be due to closure of wound in tension &/or patient negligence in following post-operative instructions.

Although recurrence of fistulous tract can also be attributed to superadded infection of sinus along with pus discharge from tract. It correlates well with the study of Hernando.⁵ Recurrence of fistula in one patient was closed between 1-4 months after its occurrence with use of buccal advancement flap procedure. But the study of Siddharth¹⁷ shows that secondary closure with Buccal Fat Pad flap is best to consider in recurrent cases of fistula as the size of tract is increased and patient is facing complications with sign and symptoms of chronic sinusitis and chronic fistulous tract.

CONCLUSION

Buccal advancement flap (BAF) is flap of choice for immediate closure of oroantral communication &/or oroantral fistula of ≤ 5 mm in the region of maxillary first and second molar. The technique is simple and good vascular supply ensures the proper healing of flap. More work needs to be done to evaluate the causes for the partial or complete loss of the flap.

REFERENCES

1. Rehman Z, Khan M, Din Q. Buccal Advancement Flap vs. Palatal Rotation Flap in management of oroantral fistula. *J Khyber Coll Dent* 2012; 2(3): 26-9.
2. Procacci P, Alfonsi F, Tonelli P, Selvaggi F, Menchini Fabris GB, Borgia V et al. Surgical Treatment of Oroantral Communications. *J Craniofac Surg* 2016; 27(5):1190-6. doi: 10.1097/SCS.0000000000002706.
3. Denes SA, Tieghi R, Elia G. The Buccal Fat Pad for Closure of Oroantral Communication. *J Craniofac Surg* 2016; 27(3):e327-30. doi: 10.1097/SCS.0000000000002579.
4. Kiran Kumar Krishanappa S, Prashanti E, Sumanth KN, Naresh S, Moe S, Aggarwal H, et al. Interventions for treating oro-antral communications and fistulae due to dental procedures. *Cochrane Database Syst Rev*. 2016; 27(5):CD011784. doi: 10.1002/14651858.CD011784.pub2. Review. Update in: *Cochrane Database Syst*
5. Hernando J, Gallego L, Junquera L, Villareel P. Oroantral communication. A retrospective analysis. *J Oral and Maxillofac Surg, Oral Med, Oral Pathol, Oral Cr Buccal* 2010; 15:499-503.
6. De Biasi M, Maglione M, Angerame D. The effectiveness of surgical management of oroantral communications: a systematic review of the literature. *Eur J Oral Implantol*. 2014; 7(4):347-57. Review. PubMed PMID: 25422823.
7. Bravo Cordero G, Minzer Ferrer S, Fernández L. Odontogenic sinusitis, oro-antral fistula and surgical repair by Bichat's fat pad: Literature review. *Acta Otorinolaringol Esp* 2016; 67(2):107-13. doi: 10.1016/j.otorri.2015.03.001.
8. Abuabra A, Cortex AL, Passeri LA, De Moraes M, Moreira RWF. Evaluation of different treatment for oroantral communications. Experience of 112 cases. *Int J Oral and Maxillofac Surg* 2006; 35:155-8.
9. Klara S, Vanija VT. Treatment of Oroantral fistula. *Acta stomato Croat* 2002; -36(1): 135-40.
10. Meirelles RC, Navas RM. Oroantral fistula and genian mucosal Flap: A review of 25 cases. *Rev Bras otorinolaringol* 2008; 74(1):85-90.
11. Dym H, Wolf JC. Oro Antral Communication. *Oral maxillofac Surg Clin N Am* 2012; 24:239-40.
12. Borgnova AE, Bearadinelli FV, Favale M, Maiorana C. Surgical option in Oroantral fistula Treatment. *Open Dent J* 2012;6:94-8.
13. de Souza Lopes PH, Sampaio Dde O, de Souza Menezes BL, do Nascimento DF, Torres BC. Combined palatal flap and titanium mesh for oroantral fistula closure. *Ann Maxillofac Surg* 2015; 5(1):89-92. doi: 10.4103/2231-0746.161090.
14. Bilginaylar K. Comparison of the Clinical Outcomes of Buccal Advancement Flap Versus Platelet-Rich Fibrin Application for the Immediate Closure of Acute Oroantral Communications. *J Craniofac Surg* 2019; 30(1):e45-e49. doi: 10.1097/SCS.0000000000004958. PubMed PMID: 30480627.
15. Cankaya AB, Erdem MA, Cakarer S, Isler SC, Demircan S, et al. Reliability of Two Surgical Methods for Oroantral Communication Closure; A Clinical Study of 20 Patients. *Otolaryngology* 2012; 2:113. doi:10.4172/2161-119X.1000113
16. Belmehti A, El Harti K. Management of oroantral communication using buccal advanced flap. *Pan Afr Med J*. 2019 Oct 3;34:69. doi: 10.11604/pamj.2019.34.69.19959.
17. Siddarth P, Phull G, Chugh D, Sheokand P. Treatment of recurrent Oroantral fistula in left maxillary region: a secondary repair procedure with buccal fat pad advancement technique. *Health Sci*.2010; 1(4):47-9.
18. Durnovo EA, Fedorichev AO, Homutinnikova NE. Modern view on the problem of oroantral fistula closure: literature review. *Stomatologiya (Mosk)*. 2019;98(2):76-80. doi: 10.17116/stomat20199802176.
19. Merlini A, Garibaldi J, Piazzai M, Giorgis L, Balbi P. Modified double-layered flap technique for closure of an oroantral fistula: Surgical procedure and case report. *Br J Oral Maxillofac Surg*. 2016; 54(8):959-61. doi: 10.1016/j.bjoms.2016.06.011.
20. Demetoglu U, Ocak H, Bilge S. Closure of Oroantral Communication With Plasma-Rich Fibrin Membrane. *J Craniofac Surg*. 2018 Jun;29(4):e367-e370. doi:10.1097/SCS.0000000000004360. PubMed PMID: 29485557.
21. Yang S, Jee YJ, Ryu DM. Reconstruction of large oroantral defects using a pedicled buccal fat pad. *Maxillofac Plast Reconstr Surg*. 2018 Apr 5; 40(1):7. doi: 10.1186/s40902-018-0144-6.
22. Ram H, Makadia H, Mehta G, Mohammad S, Singh RK, Singh N, Singh G. Use of Auricular Cartilage for Closure of Oroantral Fistula: A Prospective Clinical Study. *J Maxillofac Oral Surg*. 2016 Sep; 15(3):293-299.
23. Sharma SP. Three-Layered Closure of Persistent Oroantral Fistula Using Chin Graft, Buccal Fat Pad, and Buccal Advancement Flap: A Case Report with Review of Literature. *Case Rep Dent*. 2019; 2019:8450749. doi: 10.1155/2019/8450749.