

# THE RELATION OF POSTERIOR VIBRATING LINE TO THE FOVEA PALATINE IN CLASS I, CLASS II AND CLASS III SOFT PALATE TYPES

Shafi Ullah Khan<sup>1</sup>, Akbar Khalil<sup>2</sup>, Faiza Abdul Hakam<sup>3</sup>

<sup>1</sup>Department of Prosthodontic, Khyber College of Dentistry, Peshawar.

<sup>2</sup>Head Department of Prosthodontic, Khyber College of Dentistry, Peshawar.

<sup>3</sup>Demonstrator Department of Prosthodontic, Khyber College of Dentistry, Peshawar.

## ABSTRACT

**Objective:** To determine the frequency of the location of vibrating line with respect to fovea palatini in different soft palate types among patients.

**Materials and Methods:** This cross-sectional study was conducted in Khyber College of dentistry, Peshawar, Pakistan. 121 subjects were included in this study. Clinical examination was carried out to examine the location of vibrating line whether it is anterior, posterior or at the fovea palatini in different soft palate types.

**Results:** Our study result shows that in 57(47.11%) subjects vibrating line was in front, in 63(52.06%) subjects it was at and in 1(0.83%) subject it was behind the fovea palatini. Eighty five (70.25%) patients had Class I, 29 (23.97%) patients had Class II and 7 (5.78%) patients had Class III soft palatal types.

**Conclusion:** The vibrating line was predominately found at or anterior to the fovea palatini in subjects with Class I, II and III soft palates.

**Keywords:** Fovea Palatini, Vibrating Line, Posterior Palatal Seal, Postdam.

## INTRODUCTION

Treating edentulous patient is a difficult task.<sup>1</sup> A well retained maxillary complete denture requires well-fitting tissue surface and a peripheral seal which is created by soft tissue draping over denture border.<sup>2</sup> This kind of seal is difficult to achieve along the posterior border of maxillary complete denture.<sup>3</sup> Posteriorly, the seal is achieved by extending posterior border of the complete denture to the posterior vibrating line and slightly displacing the soft tissue.<sup>4</sup> Posterior vibrating line is itself an imaginary line running across the soft palate from one hamular notch to other passing in close proximity to fovea palatini.<sup>5</sup>

Fovea palatini are two small pits or depressions

### Correspondence:

Dr. Shafi Ullah Khan

Assistant Professor

Department of Prosthodontic, Khyber College of Dentistry, Peshawar.

Email: shafidentist@yahoo.com

Contact: +92-03339108320

in posterior aspect of soft palatal mucosa, one on each side of the mid-line at or near attachment of soft palate to the hard palate.<sup>6</sup> They are the ductal openings and recipients of distributaries of ducts of the surrounding clusters of mucous glands. They are not constantly present as are those of the major salivary glands.<sup>7</sup> Fovea palatini have been traditionally considered to be useful guide in locating the posterior vibrating line.<sup>5</sup>

Existing literature shows variable locations of vibrating line in relation to fovea palatini. It has been reported that position of vibrating line may lie anterior to, at or posterior to the fovea palatini.<sup>8,9</sup>

The location of vibrating line in relation to fovea palatini varies with the contour of the soft palate.<sup>10</sup> The soft palate is movable part of the palatal anatomy posterior to the hard palate and its movement and degree of displacability varies in individuals.<sup>6</sup>

Millsaps proposed three classes of palatal throat

form depending upon angle formed between hard and soft palate. In class I, soft palate is horizontal or turns downward around 10 degrees angle to the hard palate at mid-palatal raphe. In class II, soft palate turns down around 45 degrees angle, while in class III, soft palate turns downward around 70 degrees respectively.<sup>11</sup>

According to a study by Akhtar N et al, in 49% cases posterior vibrating line was located at fovea palatine, in 47% cases it was behind and in 13% cases it was in front of fovea palatine.<sup>12</sup> While in another study by Kumar B, in 34% cases the posterior vibrating line was located at fovea palatini, in 66% it was in front and none behind the fovea palatine.<sup>13</sup>

With this background in mind, the present study was planned to determine the reliability of using fovea palatini for approximating the location of the vibrating line in our local population. Local data in this regard is lacking. Therefore, it is important to study this anatomic landmark and try to establish its usefulness in approximating the position of the vibrating line. It is hoped that this study will help in a clinical setting to anatomically locate the position of the vibrating line instead of vaguely judging it inside the mouth.

## MATERIALS AND METHODS

This cross-sectional survey was conducted in Department of Prosthodontics at Khyber College of dentistry Peshawar, Pakistan from June 2018 to February 2019. By using WHO sample size calculator, the total sample size was 121 by taking 13% prevalence of vibrating line in front of fovea with 95% confidence interval and 6% margin of error. Consecutive sampling was done. The patients meeting the inclusion criteria such as both gender (male and female), age range from 20 to 70 years, having normal pink color palatal mucosa with clinically visible fovea palatini in all soft palate types were selected. Those patients with history of craniofacial trauma or surgery, congenital and acquired craniofacial anomalies, any inflammation or pathology of palatal mucosa and limited opening of mouth were excluded from the study. The patients meeting the inclusion criteria were selected and the informed consent was taken verbally and written in Pushto and Urdu language from each patient regarding their willingness and participation in the study and the selected patients were divided into five groups, after

collection of data according to their age:

- Group A: 20 – 30 years
- Group B: 31 – 40 years
- Group C: 41 – 50 years
- Group D: 51 – 60 years
- Group E: 61 – 70 Years

The selected patients were seated on dental unit in an upright position with head held erect and asked to open the mouth wide. The palate of each patient was examined for the visibility of fovea palatini and soft palatal type (Class I, Class II and Class III). After that the selected patients were instructed to pronounce “ah” sound in short bursts in a normal unexaggerated fashion repetitively to rehearse the “Ah” method until they became familiar with it. Mucosa of palate was dried using 2 X 2 cm gauze, as the soft palate moved up when the patients attempted to pronounce the “ah” sound, both the fovea palatini and the vibrating line were marked using an indelible pencil and the procedure was repeated twice to verify the accuracy of markings. The findings for the vibrating line were recorded in proforma as to whether it existed anteriorly, at or posteriorly to the fovea palatine.

## RESULTS

The results were analyzed using SPSS version 22. The mean age of the subjects were calculated. Frequency and percentage was calculated for genders, age and various location of vibrating line with respect to fovea palatini. Stratification of position of vibrating line was done with regard to gender, age and type of palatal form. A total of 121 patients fulfilling the selection criteria were examined. Out of them 58 (47.9%) were males and 63 (52.1%) were females. The mean age of the study sample was  $40.47 \pm 15.68$  years. Group A has the highest and group E has the lowest number of patients (fig 1). Regarding palatal type form, 85 (70.25%) patients had Class I, 29 (23.97%) patients had Class II and 7 (5.78%) patients had Class III (fig 2). Fifty seven (47.11%) patients had vibrating line located anterior to fovea palatine, 63 (52.06%) patients had vibrating line located at fovea palatine while 1(0.83%) patient had vibrating line located posterior to the fovea palatine (fig 3). Chi-square test was used to analyze the correlation of vibrating line location with gender,

age and palatal type form. Statistically no significant difference was seen (Table 1, 2 and 3).

**Table: 1 Correlation between gender and location of fovea palatini**

	Position of vibrating line			Total
	Anterior to vibrating line	At fovea palatini	Posterior to fovea palatini	
Male	26	31	1	58
Female	31	32	0	63
Total	57	63	1	121

Chi square= 0.150

**Table: 2 Correlation between age groups and location of fovea palatine**

Age group	Position of vibrating line			Total
	Anterior to Fovea Palatini	At fovea palatini	Posterior to fovea palatini	
20-30	21	21	0	42
31-40	16	10	0	26
41-50	8	14	0	22
51-60	6	11	0	17
61-70	6	7	1	14
Total	57	63	1	121

Chi Square = 0.535

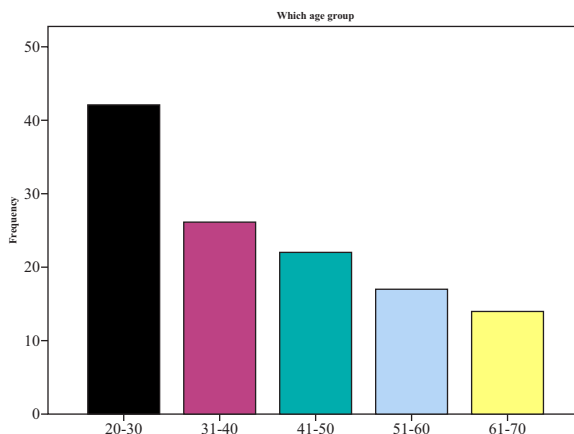
**Table: 3 Correlation between type of palatal forms and location of fovea palatini**

Palatal forms	Position of vibrating line with respect to fovea palatini			Total
	Anterior to fovea palatini	At fovea palatini	Posterior to fovea palatine	
Class I	41	44	0	85
Class II	12	16	1	29
Class III	4	3	0	7
Total	57	63	1	121

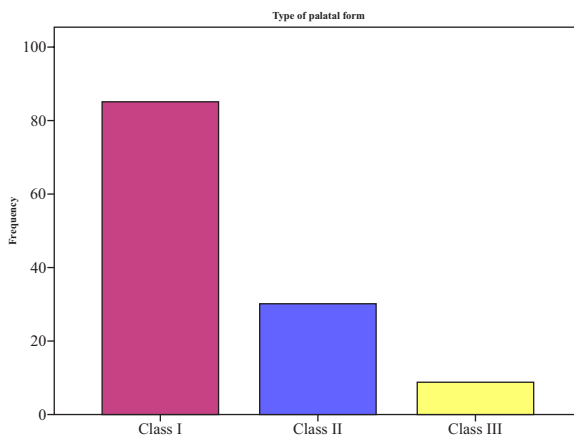
Chi square =0.446

**DISCUSSION**

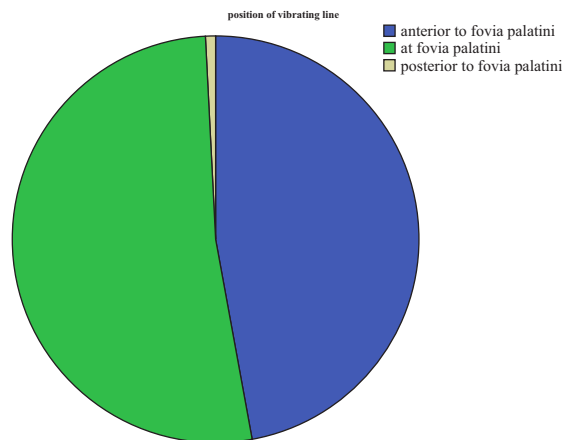
Multiple techniques are used for location of vibrating line. These include phonation of “Ah” sound, palpatory method, swallowing method and nose blowing or Valsalva maneuver. In our study we used to find the location of posterior vibrating line by asking the subject to say “Ah” because it’s



**Fig 1: Frequency of different age groups**



**Fig 2: Frequency of Palatal type form**



**Fig 3: Frequency of vibrating line with respect to Fovea palatini**

simple and mostly taught in dental schools of US, Canada and Pakistan.<sup>16,17</sup>

In current study, results revealed that vibrating line lies in front, at and behind the fovea palatinae in 57(47%), 63(52%) and 1(0.84%) subjects respectively. Similar results were obtained in another study conducted at prosthetic department of Lahore Medical and Dental College, Lahore by Ahmed S. According to his study the position of vibrating line with fovea palatini was anterior in 45%, at in 51% and posterior to in 4% of subjects.<sup>18</sup> The results of our study also coincide with another study done by Alousi conducted in Prosthodontics department of dentistry, Baghdad University. In this study location of vibrating line was reported 44.5% in front, 50.9% at and 6.4% behind in relation to fovea palatinae.<sup>19</sup>

However contrary to the results of our findings, Lye reported that 13% patient had vibrating line laying anterior to the foveae palatini, 17% had vibrating line located at and 69% had vibrating line lying posterior to fovea palatinae. This may be due to ethical and genetic variations. Also our study results do not coincide with the study results of Akhtar N conducted in Islamabad. According to his study vibrating line was in front in 12% subjects, in 45% subjects it was at and in 43% it was posterior to fovea palatini. Because the vibrating line is imaginary line that is more akin to an area than a clear line.<sup>20</sup> So the location can vary depending on the area of vibrating line selected as the standard with reference to fovea palatini. Alousi<sup>19</sup> concluded that fovea palatini is a reliable anatomical landmark that helps in determining post dam area of denture and that there was no significant difference between gender and location of vibrating line in relation to fovea palatini. This finding of his study is similar to the finding of our study.

Akhtar N et al, in their study concluded that the fovea palatini are unreliable anatomical landmarks for determining centre portion of posterior border of maxillary denture<sup>12</sup> while in our study the results shows that fovea palatini may be considered as reliable guides. Our study results favour the results of study of Ahmed S<sup>18</sup> and Alousi.<sup>19</sup>

## CONCLUSION

- The vibrating line was predominantly found at or anterior to fovea palatini in subjects with class I, II and III soft palates.

- Almost 70% of the subjects have class I soft palatal type.
- So within limitations of present study, it can be concluded that if present, fovea palatini are reliable anatomical landmarks to locate posterior vibrating line and to determine posterior limit of complete denture.

## REFERENCES

1. Kryszynski ZJ, Prylinski M. Carving of a master cast to obtain a posterior palatal seal of a complete maxillary denture as performed by four prosthodontics. *J Oral Sc.*2007; 49: 129-32.
2. Ettinger RL, Scandrett FR. The posterior palatal seal. A review. *Aust Dent J* 1980;25:197-200.
3. Fenn HRB, Liddelow KP, Gimson's AP. *Clinical Dental Prosthetics* 6th ed.. London: Unicorn Press; 2012.
4. Chen MS. Reliability of the fovea palatini for determining the posterior border of the maxillary denture. *J Prosthet Dent.* 1980; 43: 133-37.
5. Wicks R, Ahuja S, Jain V. Defining the posterior palatal seal on a definitive impression for a maxillary complete denture by using a nonfluid wax addition technique. *J Prosthet Dent.* 2014;112:1597-600.
6. The Glossary of Prosthodontic Terms. *J Prosthet Dent.* 2005;94:10-92.
7. Lye. The significance of the fovea palatini in complete denture prosthodontics. *J. Pros. Den.*1975, 33(5): 504-510.
8. Thapa D, Chandra S, Karki S. Verifying relationship between fovea palatini, vibrating lines and junction between hard and soft palate. *Orthodontic Journal of Nepal* 2016:32-34.
9. Bindhoo Y, Thirumurthy V, Jacob SJ, Anjanakurien, Limson KS. Posterior palatal seal: A literature review. *Int J Prosthodont Restor Dent.* 2011;1:108-14.
10. Winkler S. *Essentials of Complete Denture Prosthodontics.*2nd ed. Ish. Euro: AITBS; 2004.
11. Millsap CH. The posterior palatal seal area for complete dentures. *Dent Clin North Am.* 1964; 8: 663-73
12. Akhtar N, Tanveer S, Chaudary MAG, Ahmad S. The reliability of fovea palatinae in determining the location of vibrating line in edentulous patients. *Pakistan Oral @ Dental Journal* 2017;37(2):368-370.
13. Kumar B, Naz A, Rashid Haroon, Butt MA. Location of the Vibrating Line with Respect to Fovea Palatini in Class I, Class II and Class III Soft Palate Types. *JPDA* 2016; 25 (2):60-66.
14. Zarb GA, Bolender CL. *Prosthodontic Treatment for Edentulous Patients.* 12th ed. St. Louis: Mosby; 2004

15. Fernandes VA, Chitre V, Aras M. A study to determine whether the anterior and posterior vibrating lines can be distinguished as two separate lines of flexion by unbiased observers. *Ind J Dent Res.* 2008; 19: 335-39
16. Rashedi B, Petropoulos VC. Current concepts for determining the postpalatal seal in complete dentures. *J Prosth Dent.* 2003; 12: 265-70.
17. Chen MS, Welker WA, Puskamp FE, Crosthwaite HJ, Tranquist RA. Methods taught in dental schools for determining the posterior palatal seal region. *J Prosth Dent.* 1985; 53: 380-83.
18. Ahmed S, Das G, Rana MH and Reehana. Upper complete denture; location of vibrating line with reference to fovea palatine in determining posterior border. *Professional Med J* 2018; 25(3):419-423.
19. Alousi Y. Reliability of fovea palatina in determining the posterior palatal seal. *J Bagh Dent.* 2009; 21: 41-45.
20. Fernandes VA, Chitre V, Aras M. A study to determine whether the anterior and posterior vibrating lines can be distinguished as two separate lines of flexion by unbiased observers. *Ind J Dent Res.* 2008; 19:335-39.