

COMPARISON OF RESORBABLE WITH NON RESORBABLE PLATES TO TREAT PAEDIATRIC MANDIBULAR FRACTURES

Muhammad Adnan Akram¹, Saeed Ahmad², Tehmasub Faraz Tayyab³,
Usman Tariq², Hafiz Muhammad Majid Jehangir⁴, Muhammad Sumair Farooq⁵

¹Department of Oral & Maxillofacial Surgery, Azra Naheed Dental College, Lahore

²Department of Pediatric Oral & Maxillofacial Surgery, CHICH, Lahore

³Department of Oral & Maxillofacial Surgery, University Medical and Dental College, Lahore

²Department of Pediatric Oral & Maxillofacial Surgery, CHICH, Lahore

⁴Department of Oral Pathology, Azra Naheed Dental College, Lahore

⁵Department of Oral Biology, Azra Naheed Dental College, Lahore

ABSTRACT

Objective: The purpose of the present study was to compare the clinical efficacy and postoperative complications between resorbable and non-resorbable plates and screws in the treatment of paediatric mandibular symphysis and parasymphysis fractures.

Materials and Methods: Resorbable and non resorbable plates were used in 46 paediatric patients (age ranges 6 to 12 years, mixed dentition stage) for the treatment of mandibular symphysis and parasymphysis fractures. The variables critically observed were infection, wound dehiscence, bony union and malocclusion.

Results: Out of the 46 paediatric patients, 23 were in the non resorbable titanium plating group (group A) and 23 in the resorbable plating group (group B). Two patients showed minor infection at first week in group A and 1 patient in group B. Only one patient showed wound dehiscence at 4th week in group A. No malunion and malocclusion occurred during the observation period in both the groups.

Conclusion: The results obtained in this study showed that morbidity in both groups was matched in term of outcomes when evaluated. The avoidance of repeat surgery for plate removal is a definite advantage of using resorbable plating system.

Keywords: Paediatric Mandibular fractures, Non Resorbable Plates, Resorbable Plates.

INTRODUCTION

Mandible constitutes about 75-90% of all facial fractures. Mandibular fractures in children occur less frequently as compared with adults and they are more often minimally displaced due to thicker layer of adipose tissue covers the bone which are more elastic in nature and its stability is increased by the presence

of tooth buds within the jaw. Factors like soft tissue bulk, biomechanical characteristics of the mandible as bone density, mass and anatomic structures (normal or pathologic) creating weak areas within the bone influences mandibular fracture pattern.¹

Due to above mentioned characteristics paediatric mandible undisplaced fractures are mostly treated by closed approach. Displaced fractures may lead to loss of function and facial disfigurement ultimately requiring open reduction and internal fixation.²

Titanium is considered to be the most biocompatible metal currently and is used for manufacturing

Correspondence:

Dr. Muhammad Adnan Akram,
Senior Registrar
Department of Oral & Maxillofacial surgery,
Azra Naheed Medical & Dental College, Lahore.
Email: m.adnan.akram@hotmail.com
Contact: +92-321-4117494

all types of plates and screws nowadays. Titanium plates and screws fixation for paediatric mandibular fractures can be complicated by a mixed dentition and developing tooth crypts. The metallic nature and non resorbable property of titanium mini or micro plates and screws are associated with growth restriction, stress shielding, osteoporosis, thermal paresthesia and palpability leading to pain. The visibility, extrusion, migration and corrosion of titanium plate results in various complications like higher incidence of infection, wound dehiscence and allergic reaction. The metallic osteosynthesis may require revision surgery for plate removal in children ultimately leading to scarring, hospitalization, cost and burden on health care system.³

Currently, resorbable plates are being used to overcome problems associated with metallic plates and screws in paediatric mandibular fracture management. Bioresorbable osteosynthesis in paediatric mandibular fracture management alleviates the trauma of revision surgeries as in titanium plating system because of its property to dissolve by hydrolysis, a significant advantage over conventional titanium plate system.⁴ The purpose of this study was to compare resorbable with non resorbable plates in the management of paediatric mandibular fractures.

MATERIALS AND METHODS

Sample size:

The sample size was calculated by the following formula keeping the power of study equal to 80% and level of significance equal to 5%. The sample size is 22.

$$n = \frac{\left(Z_{1-\alpha/2} \sqrt{2p(1-p)} + Z_{1-\beta} \sqrt{p_1(1-p_1)p_2(1-p_2)} \right)^2}{(p_1 - p_2)^2}$$

(Sample Size determination in health studies version 2.0.21 WHO13)

P1 is the rate of infection in 3- Dimensional plate group = 0%

P2 is the rate of infection in Miniplate/ micro group = 29.2%

p1 – p2 is the difference between proportions = 29.2%

Z 1 – β is the desired power of study = 80%

Z 1-α/2 is the desired level of significance = 5%

n is the calculated sample size in each group = 22

Forty six paediatric patients {male 34 (73.91%) & female 12 (26.08%)} presenting to the OPD, Department of Oral and Maxillofacial surgery, The Children’s Hospital & The Institute of Child Health, Lahore having symphysis and parasymphysis fractures were equally divided into group A & B through random lottery method. Group A was treated with titanium microplate along with arch bar while patients in Group B were given resorbable plate and arch bar. The patient age range was from 6-12 years with mean age of 9.02 years. According to fracture site there were 11 symphysis fractures and 35 parasymphysis fractures. Cases of retreatment, gunshot wounds, firearm injuries and comminuted fractures of mandible were excluded from the study. Prior written informed consent with explanation regarding advantages and disadvantages of the absorbable and non-absorbable plates including the complications involved was taken from the parents of the patients. All patients were treated under general anesthesia after being deemed fit for surgery by using nasotracheal tube. IMF was achieved with arch bars during intra-operative period only. The arch bar was used to counteract the tension band in the upper border and the fracture site was approached through standard intra oral vestibular incision. The fracture site was exposed and displaced bone fragments were reduced to their anatomical location. After IMF, internal fixation will be done with plates and screws⁵. Patients in the group A were treated with titanium micro plates of 1.1mm and mini plates of 1.5mm and 2.0mm were adapted with self-threaded 4mm and 6mm length titanium screws respectively. Patients in the group B were treated with Bonamates bioresorbable plating system composed of Poly-DL-Lactic acid copolymer. After reduction and securing arch bar, the resorbable plate was applied by drilling outer cortex only. A manual tap was used to create screw threads and mono-cortical screws were used to secure plate. Care was taken not to damage developing tooth buds during this process. The wound was closed with 3/0 resorbable polyglactin sutures. IMF was released at the end of the surgical procedure. Patients was placed on standard 10 days antibiotic regimen consisting of penicillin, clindamycin or cephalosporin with adequate analgesics and instructed a strict soft chew diet for 14 days with maintenance of oral

hygiene. Patients was reviewed after intervals of 1 week, 4 weeks and then after 12 weeks. The arch bar was removed after 4 weeks and the titanium mini or micro plates and screws were removed after 12 weeks. Radiographs were carried out immediately after treatment, at 1st week, 4th week and 12th week postoperatively.

RESULTS

There were 73.91% (34) males and 26.08% (12) females in this study (Fig: 1). 73.9% of the fractures were of parasymphysis fractures and 26.10% were of symphysis (table: 1).

Postoperative complications were noted. The patients were observed for infection, wound dehiscence, bony union and malocclusion. Infection at 1st week was 8.6 % in group A and 4.3% in Group B respectively. None of the patients showed sign of infection on 4th and 12th week. Wound dehiscence was observed in one patient in Group A on 4th week (4.3%). Wound dehiscence was observed in 1 patient in Group A in the 4th week which resolved in follow up visit on 12 week. All the patients in both groups showed bony union and none of the patients showed malunion on 1st, 4th and 12th weeks respectively.

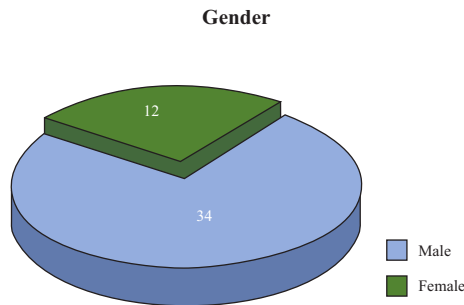


Fig 1: Gender distribution for anterior

Table: 1 Site distribution of Pediatric Mandibular Fractures in both groups

Diagnosis	Group A		Group B		Total: Group A+ B	
	Count	% age	Count	% age	Count	% age
Symphysis	5	21.70%	6	26.10%	11	23.91%
Parasymphysis	18	78.3%	17	73.9%	35	76.08%
Total	23		23		46	

Etiology
 ■ Group A ■ Group B

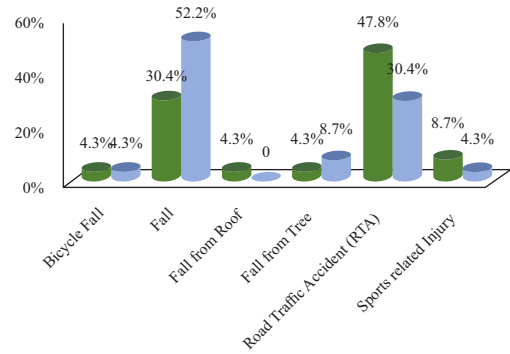


Fig 2: Etiology for anterior mandibular fractures showing fall to be the main cause of fracture

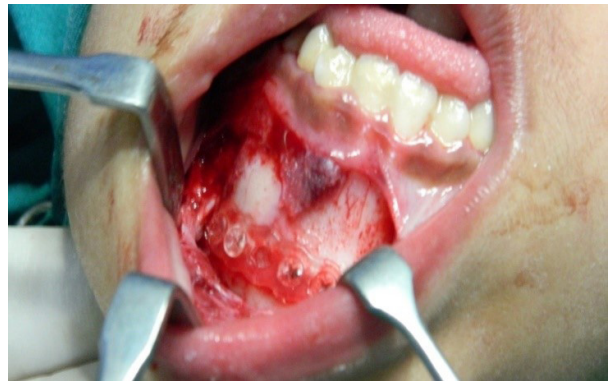

Fig 3: Open reduction and internal fixation of right parasymphysis fracture with resorbable plate and screws

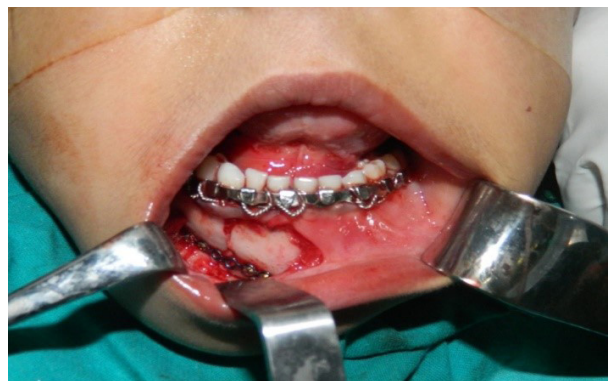

Fig 4: Open reduction and internal fixation of right parasymphysis fracture with titanium micro plate and screws

DISCUSSION

The development of titanium osteosynthesis has undergone with great progress in craniomaxillofacial surgery. This holds true for the management of adult maxillofacial trauma but is not applicable to pediatric maxillofacial trauma due to some major factors like, mixed dentition, eruption of teeth, developing tooth buds, short roots and growth issues.⁶ In this study, standard titanium plates and screws were compared with bioresorbable plates and screws for the treatment of isolated symphysis and parasymphysis mandibular fractures in pediatric patients. Forty six pediatric patients with mixed dentition phase were included. Predominant gender in the present study was male patients which in line with many other studies.⁷ The probable reason was that boys are more boisterous than girls and spend more time in outdoor.⁸

Main etiological factors in pediatric patients were fall, sports related injuries and road traffic accidents and falls being at the top. In the countries of Indian subcontinent such as Pakistan, Tree climbing, kite flying and small multistory houses are common associated factors in receiving early age trauma due to fall.⁹

In this study post-operative complications observed were infection, wound dehiscence, bony union and malocclusion. At 1st week, in group A, infection was seen in two patients and in group B, only one patient was suffered from infection. At 4th and 12th week in both group A and group B, no infection was seen. Thus bioresorbable plate is comparable treatment option for pediatric mandibular fractures as compared to titanium plates with respect to infection. The infection rate in this study is comparable to that of internationally published data.⁵ Patients were observed postoperatively for wound dehiscence at first week, fourth week and twelfth week. In group A, at 4th week only one patient showed wound dehiscence while no patient showed wound dehiscence in group B treated with resorbable plate. This complication can be explained by the fact that study population was paediatric, it was difficult to keep the patients compliant with oral hygiene instructions. Wound irrigation and improved oral hygiene resulted in wound healing.

In our study, there was no incidence of malunion and malocclusion in both groups and which are com-

parable with that of international data.^{10, 11}

CONCLUSION

Resorbable plates are undoubtedly exorbitant when compared with titanium micro plating system. But the factors like, less infection rate, avoidance of second surgery for plate removal, no documented growth restriction, no stress shielding, no thermal paresthesia, no osteoporosis and no interference with radio-diagnostic and radio-therapeutics techniques make resorbable plating system clearly supercilious to other available options.

REFERENCES

1. El-Saadany WH, Sadakah AA, Hussein MM, Saad KA. Evaluation of using ultrasound welding process of biodegradable plates for fixation of pediatric mandibular fractures. *Tanta Dental Journal*. 2015 Dec 1; 12:S22-9.
2. Goth S, Sawatari Y, Peleg M. Management of pediatric mandible fractures. *Journal of Craniofacial Surgery*. 2012 Jan 1; 23(1):47-56.
3. Singh M, Singh RK, Passi D, Aggarwal M, Kaur G. Management of pediatric mandibular fractures using bioresorbable plating system—Efficacy, stability, and clinical outcomes: Our experiences and literature review. *Journal of oral biology and craniofacial research*. 2016 May 1; 6(2):101-6.
4. Li Z, David O, Li ZB. The use of resorbable plates in association with dental arch stabilization in the treatment of mandibular fractures in children. *Journal of Cranio-Maxillofacial Surgery*. 2014 Jul 1; 42(5):548-51.
5. Lee HB, Oh JS, Kim SG, Kim HK, Moon SY, Kim YK, Yun PY, Son JS. Comparison of titanium and biodegradable miniplates for fixation of mandibular fractures. *Journal of Oral and Maxillofacial Surgery*. 2010 Sep 1; 68(9):2065-9.
6. An J, Jia P, Zhang Y, Gong X, Han X, He Y. Application of biodegradable plates for treating pediatric mandibular fractures. *Journal of Cranio-Maxillofacial Surgery*. 2015 May 1; 43(4):515-20.
7. Ferreira PC, Barbosa J, Amarante JM, Carvalho J, Rodrigues AG, Silva AC. Associated injuries in pediatric patients with facial fractures in Portugal: Analysis of 1416 patients. *Journal of Cranio-Maxillofacial Surgery*. 2015 May 1; 43(4):437-43.
8. Ahmad S, Akram MA, Mirza AI, Nayyar K, Shah IA, Tariq U. Comparison of Microplate and Arch Bar with 3D Microplate in the Management of Pediatric Anterior Mandibular Fractures. *Med Forum* 2019;30(8):45-49.
9. Akhtar, M.U., Rafique, F.C.M., Shah, A.A., Akhtar, N. The prevalent age group, cause and site of pediatric facial bone trauma at two tertiary units in Pakistan. *Ann*

- King Edward Med Uni. 2006 12: 145-52.
10. Glazer M, Joshua BZ, Woldenberg Y, Bodner L. Mandibular fractures in children: analysis of 61 cases and review of the literature. International journal of pediatric otorhinolaryngology. 2011 Jan 1;75(1):62-4.
 11. Sheta MS, Shoushan MM, Hussein MM, Elaal SA. Evaluation of using microplates osteosynthesis for pediatric mandibular fractures. Tanta Dental Journal. 2015 Sep 1;12(3):149-55.
 12. Andrade NN, Choradia S. An institutional experience in the management of pediatric mandibular fractures: A study of 74 cases. Journal of Cranio-Maxillofacial Surgery. 2015 Sep 1;43(7):995-9.
 13. Aizenbud D, Hazan-Molina H, Emodi O, Rachmiel A. The management of mandibular body fractures in young children. Dental Traumatology. 2009 Dec;25(6):565-70.