

Case Report

ORTHODONTIC MANAGEMENT OF THE LABIALLY IMPACTED MAXILLARY CANINE

*Sarwat Memon, **Mubassar Fida

*Ziauddin College of Dentistry, Karachi, Pakistan.

**The Aga Khan University Hospital, Karachi, Pakistan

ABSTRACT

Objective: *An impacted tooth is any tooth that is prevented from reaching its normal position in the mouth by tissue, bone, or another tooth. Maxillary canines are the most commonly impacted teeth, second only to third molars. Maxillary canine impaction occurs in approximately 1-2% of the population and is twice as common in females as it is in males. Approximately one-third of impacted maxillary canines are located labially and two-thirds are located palatally. Canine impaction can be caused by various factors which include space deficiency, disturbances in tooth eruption sequence, trauma, retention of primary canine, premature root closure, rotation of tooth buds, as well as localized pathological lesions (cysts, odontomas). If impactions are uncorrected, the results are often both functionally and esthetically unsatisfactory. This case report present treatment of a female patient with impacted right maxillary canine. The patient was treated orthodontically with extraction of all first premolars.*

Key words: *Impaction, Maxillary canine impaction, Labially impacted canine, impaction management, Orthodontic treatment*

INTRODUCTION

Impaction of the maxillary canine is a condition in which the tooth is embedded in the alveolus and its eruption is prevented^{1,2}. Maxillary canine impaction is a frequently encountered problem in orthodontic practice³. Impacted maxillary canine can be labially or palatally placed. Eighty-five per cent of impacted maxillary permanent cuspids are palatal and 15% are labial². Several etiologic factors for canine impactions have been proposed: localized, systemic, or genetic. Treatment options for impactions include early diagnosis and interceptive treatment to orthodontic management either by non-extraction or extraction modalities, either by surgical exposure alone or by surgical exposure and attachment of a bracket and ligature for orthodontic extrusion, forced eruption using micro-implants, surgical removal and autotransplantation²⁻⁶.

CASE REPORT

A 13 year and 4 month old female patient reported to the Department of Orthodontics with the chief complaint of "Upper tooth not erupting and stuck inside gum". She had an insignificant medical history. The patient presented a symmetrical face and a convex profile with incompetent lips. Intraoral examination revealed a dental Class I incisor malocclusion, impacted right maxillary canine which was not clinically palpable, a 5 mm overjet, and 1 mm centre line discrepancy. Cast analysis showed severe space deficiency in the maxilla and mandible, upper right lateral incisor and both upper first premolars were in crossbite (Figures 1). A panoramic radiograph and occlusal view confirmed that right upper canine was buccally impacted. Cephalometric analysis (Figure 2) showed a mild skeletal Class II relationship (ANB angle = 6°) with normal vertical proportions (FMA= 28°).

The treatment plan, after overall considering the complete nature of the impaction, facial profile, lip position, smile height, crowding and the cephalometric and dental cast analyses was to improve the facial esthetics along with the dental relations. Therefore, extractions of all first premolars, surgical exposure of right upper canine, upper and lower pre-adjusted

Correspondence:

Dr. Sarwat Memon

Assistant Professor

Department of Orthodontics

Ziauddin College of Dentistry, Karachi

Cell: +92-321-3810143, +92-21-35820132

Email address: sarwatmqsood@yahoo.com

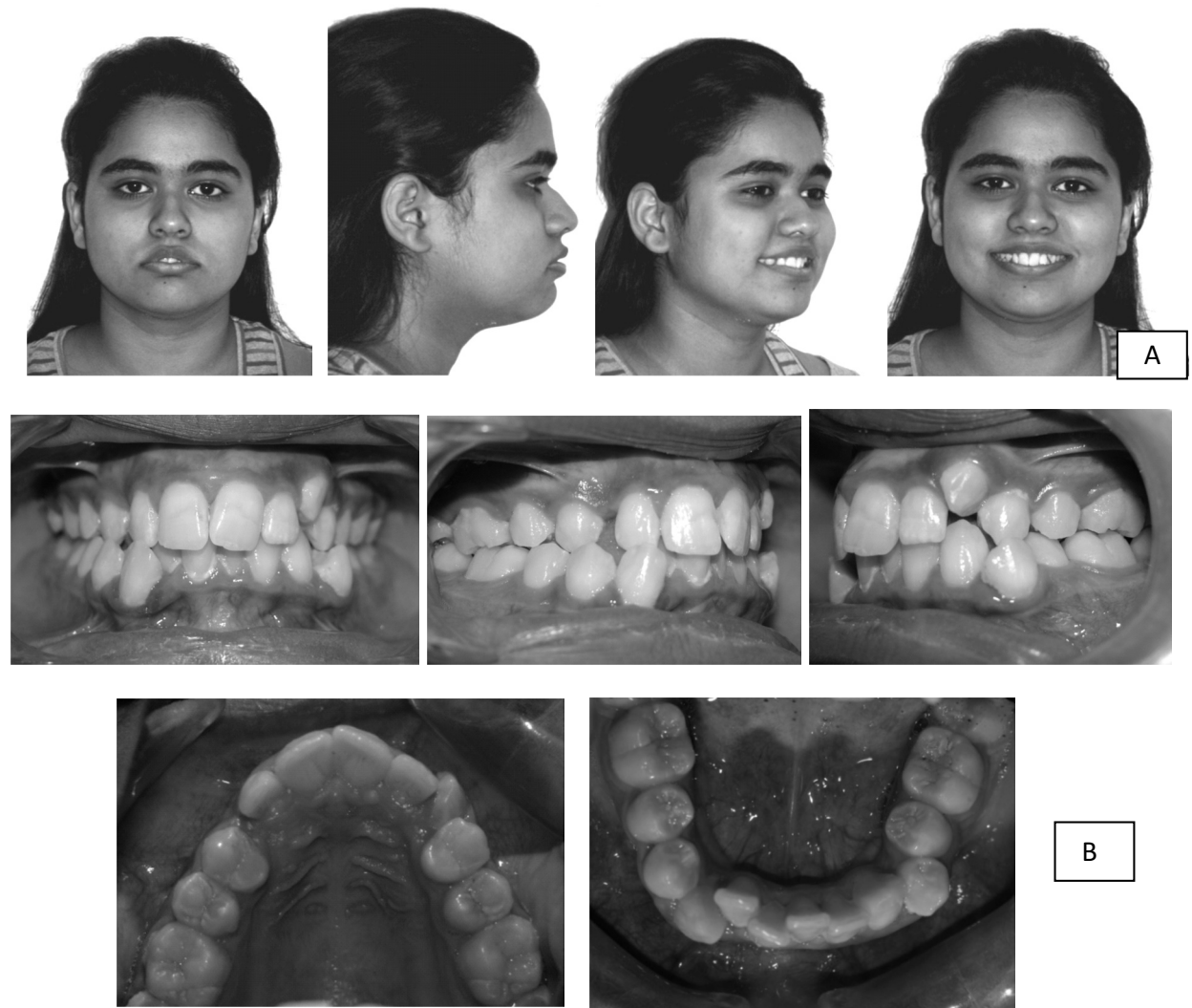

Figure 1: Pre-treatment photographs (a) extra-oral (b) intraoral

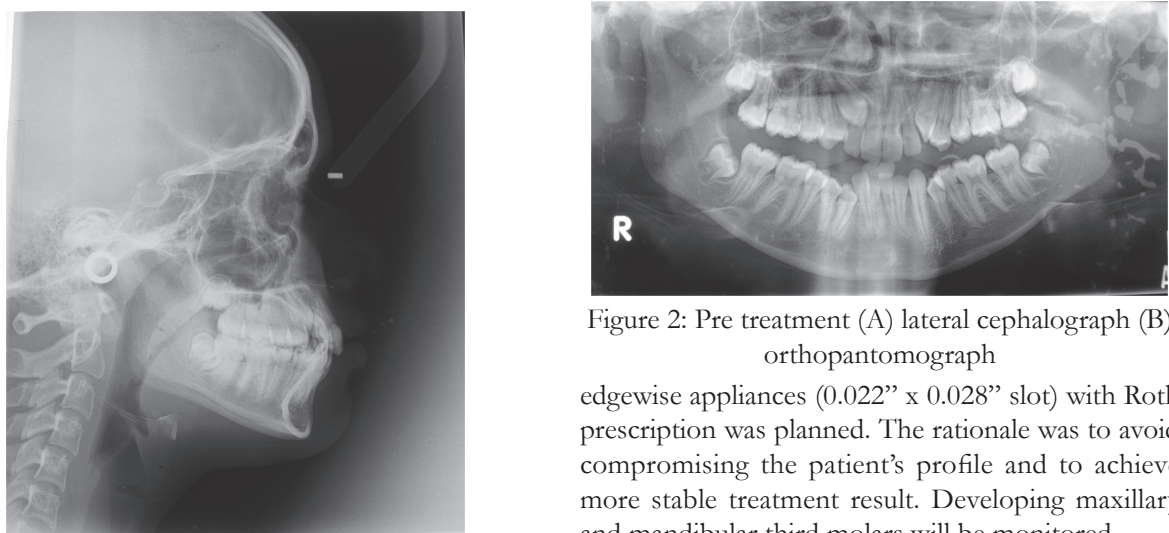


Figure 2: Pre treatment (A) lateral cephalograph (B) orthopantomograph

edgewise appliances (0.022" x 0.028" slot) with Roth prescription was planned. The rationale was to avoid compromising the patient's profile and to achieve more stable treatment result. Developing maxillary and mandibular third molars will be monitored.

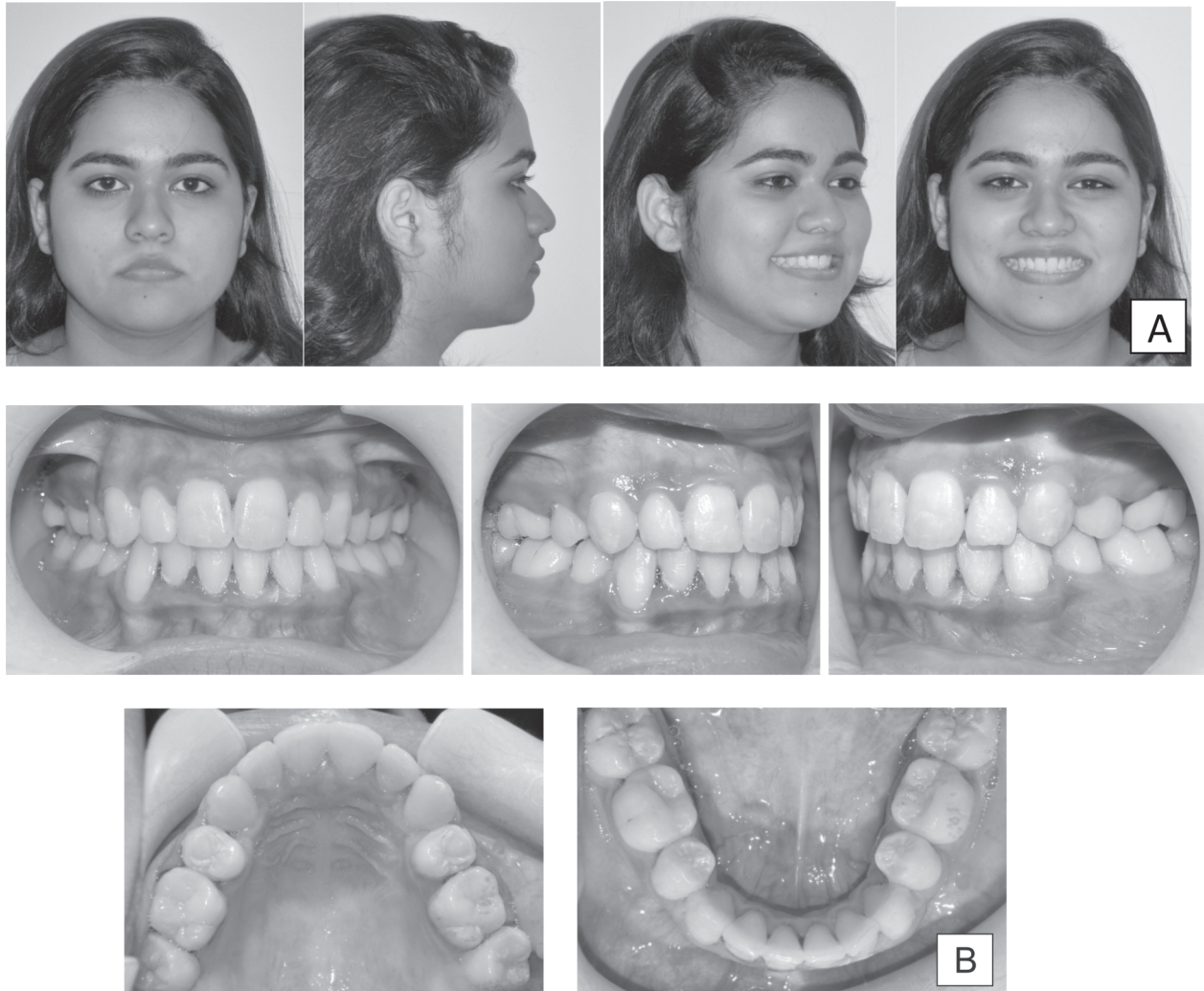

Figure 3: Post-treatment photographs: (a) extra-oral (b) intraoral

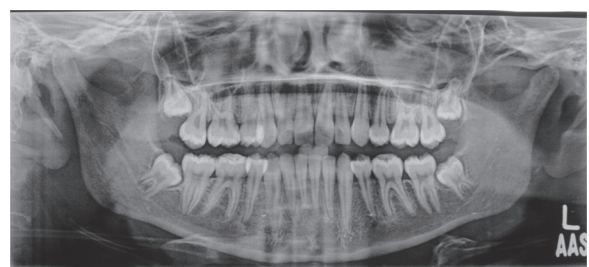
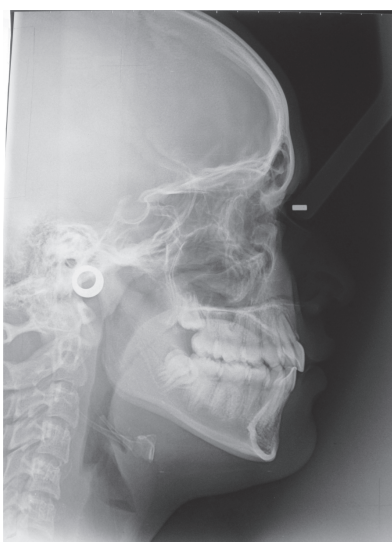
Figure 4: Post treatment (a) lateral cephalograph (b) orthopantomograph (5.11.2011)

Treatment alternatives discussed with patient were (1) Surgical removal of impacted tooth (2) Auto transplantation of impacted tooth once sufficient space is created with extraction of first premolars.

Treatment was initiated by extracting all first premolars followed by banding of permanent first

molars and bonding of teeth. Leveling and alignment was started with 0.012" NiTi Wire and was carried upto 0.016" NiTi arch wire and then 0.020" Stainless steel was placed with open coil spring between right maxillary lateral incisors and second premolar to create space for impacted right maxillary canine which was deemed to be surgically exposed. However, after sufficient space opening canine tip started to erupt without surgical exposure. One month later, button was bonded and orthodontic traction force on right upper canine with power thread was started to bring it in arch. After 4 months of treatment, bracket was bonded on canine and 0.016" NiTi archwire was engaged. Alignment of the canine and maxillary and mandibular dentition greatly improved as the wire progressed from 0.016" to a 0.017 x 0.025" NiTi archwire.

After the right maxillary labially placed canine was corrected and a good occlusal relationship was attained. Upper and lower 0.017 x 0.025" Stainless Steel wires were inserted. Finally pre-debond OPG was evaluated for root paralleling bends and settling elastics given were given. Patient compliance in using the elastics for settling was excellent. Total treatment time was 25 months. On the day of de-bonding, maxillary and mandibular second premolar-to- second premolar fixed retainer were bonded. To ensure continued satisfactory post-treatment alignment of the maxillary and mandibular anterior dentition, the continued use of retainers was recommended indefinitely.

Post-treatment facial photographs showed a pleasant smile. The favorable soft tissue drape facilitated orthodontic camouflage of the Class II skeletal pattern, without detriment to dentofacial appearance. Lips were competent at the end of treatment, with the upper incisors under the control of the lower lip. Post-treatment intraoral photographs and dental casts show satisfactory dental alignment, Class I canine relationship on both sides, and normal overjet and overbite [Figure 3]. The patient was satisfied with her teeth and profile. Good intercuspation, interproximal contacts, and satisfactory root parallelism were achieved [Figure 4].

DISCUSSION

Labial impaction of an upper canine is either due to ectopic migration of the canine crown over the root of the lateral incisor or insufficient space in the arch caused by a midline shift of dental origin³. Arch length tooth material discrepancy is the most common

cause for the labial impaction of canines^{5,7}. Maxillary canines that are potentially impacted or ectopically erupting may be inadvertently overlooked in the mixed dentition patient. This is due to individual variations in eruption patterns and timing. Periodic panoramic and selective periapical radiographs along with a careful clinical examination that includes intraoral palpation permits early diagnosis of unerupted and potentially impacted permanent canines^{2,8}. When such a diagnosis is apparent, timely interceptive therapy may then be instituted^{2,6,9}.

Extraction of the maxillary deciduous canine at an early age of eight or nine years will enhance the eruption and self-correction of labial or intra-alveolar maxillary canine impaction^{5,9}.

The amount of space in the dental arch for an unerupted canine can be assessed by performing a space analysis with a full set of orthodontic records. If sufficient space is required in the arch then it can be gained by expansion of the maxillary arch, proclination of maxillary incisors and extraction of the permanent premolars. A surgical exposure of the impacted tooth is indicated when the tooth does not erupt spontaneously after creating enough space in the arch and should be attempted six months after the completion of root formation⁸⁻¹⁰.

Milberg¹¹ reported a case of a patient with bilateral labial impaction of maxillary canines causing pressure resorption on the lateral aspects of the maxillary central incisors. Their orthodontic treatment plan included extraction of the impacted canines, positioned between the central and the lateral incisors. Sachan and Chaturvedi³ reported two cases of extraction treatment approach for buccally displaced or ectopic canine in a patient with severe crowding in the mandibular arch. They concluded that malocclusion with severe crowding is difficult to treat without extraction. Non-extraction treatment of ectopic canines can compromise the patient's profile and can cause internal or external root resorption of teeth adjacent to the ectopic canine. Similarly in this case report adequate results were achieved through an extraction treatment approach. If the four premolars were not extracted, it might have resulted in proclination of the maxillary and mandibular anterior teeth with a harmful result to the patient's soft tissue profile. By extraction treatment approach, it is much easy to correct the crowding and achieve more stable results.

Gracco et al¹² treated a 14-year-old female patient with buccally impacted upper right permanent canine and supernumerary tooth impeding canine eruption with extraction of supernumerary tooth, surgical exposure of canine with closed eruption technique and orthodontic wire traction. However in the present case it was planned to extract all first premolars followed by surgically exposure of the canine with closed eruption technique and orthodontic wire traction. But canine started to erupt spontaneously after extraction of premolars and surgical exposure of canine was not done.

The prevalence of canine impaction is low in general population, but the management of transposed teeth especially impacted canine, must be assessed on case to case basis³. As this type of dental anomaly causes many problems in orthodontic management, many factors that affect the treatment results must be considered, such as esthetics, occlusion, treatment period, patient comfort, patient cooperation, and periodontal support. However, it is possible to orthodontically treat this challenging anomaly in an efficient way and achieve promising results. This may also provide orthodontists with the best understanding of how to resolve similar malocclusions in the future.

REFERENCES

1. Park JH, Srisurapol T, Tai K. Impacted maxillary canines: diagnosis and management. *Dent Today*. 2012; 31: 64-6.
2. George litsas, Ahu acar. A review of early displaced maxillary canines: etiology, diagnosis and interceptive treatment. *open dent j*. 2011; 5: 39-47.
3. Sachan A, Chaturvedi T P. Orthodontic management of buccally erupted ectopic canine with two case reports. *Contemp Clin Dent* 2012; 3:123-8.
4. Sumitra. Orthodontic-surgical treatment of bilateral maxillary canine impaction. *Contemp Clin Dent*. 2012; 3: 363-6.
5. Jan H. Amin E, Nazir R. Orthodontic pull out of an ectopic canine through novel "HUJ" loop — a case report. *Pakistan Oral & Dent. Jr*. 2009;1; 35-40.
6. Park HS, Oh YH. Forced eruption of a labially impacted canine using joined micro-implants. *J Clin Orthod*. 2010; 44:108-13.
7. Radha Katiyar, Pradeep Tandon, Gyan P. Singh, Akhil Agrawal, T. P. Chaturved. Management of impacted all canines with surgical exposure and alignment by orthodontic treatment. *Contemp Clin Dent*. 2013; 4: 371-3.
8. Porus ST, Munim K. Management of labially impacted canine—a case report. *J Indian Dent Assoc*. 1979; 51: 277-9.
9. de Mendonça MR, Verri AC, Martins LP, Fabre AF, Cuoghi OA. Interceptive approach to treatment of impacted maxillary canines. *J Craniofac Surg*. 2012; 23:16-9.
10. Bishara SE. Impacted maxillary canines: a review. *Am J Orthod Dentofacial Orthop* 1992; 101:159-71.
11. Milberg DJ. Labially impacted maxillary canines causing severe root resorption of maxillary central incisors. *Angle Orthod*. 2006; 76: 173-6.
12. Gracco A, Maltoni I, Maltoni M, Zoli L. Eruption of a labially impacted canine using a closed-flap technique and orthodontic wire traction. *J Clin Orthod*. 2012; 46: 625-30.