

# MORPHOLOGICAL EFFECT OF NICOTINE ON RECONSTITUTED MODEL OF AN INFLAMED ORAL MUCOSA AN IN VITRO STUDY

Muhammad Nauman Sheikh<sup>1</sup>, Asmat Ullah<sup>2</sup>, Sajid Hanif<sup>3</sup>, Faisal Pasha<sup>4</sup>,  
Muhammad Irfan Khan<sup>5</sup>, Sadaf Rauf<sup>6</sup>, Zahur Qayyum<sup>4</sup>

<sup>1</sup>Department of Oral Pathology, College of Dentistry Baqai Medical University, Karachi.

<sup>2</sup>Department of Oral Medicine, Khyber College of Dentistry, Peshawar.

<sup>3</sup>Department of Oral Pathology, Karachi Medical and Dental College, Karachi.

<sup>4</sup>Department of Oral Surgery, Women Medical and Dental College, Abbottabad.

<sup>5</sup>Department of Oral & Maxillofacial Surgery, LRH Peshawar.

<sup>6</sup>Department of Dermatology, KTH/KMC Peshawar.

## ABSTRACT

**Objective:** To investigate the effect of nicotine on the morphology of an inflamed reconstituted oral mucosa in vitro when treated for 24 hours.

**Materials and Methods:** This observational laboratory-based study focuses on the effects of nicotine on an in vitro reconstituted model oral mucosa. The reconstituted human epithelium model used in the study was prepared and supplied by Skin Ethic Laboratories, Nice, France. The effect of the different treatments of nicotine on tissue morphology was assessed using formalin-fixed paraffin wax sections and haematoxylin and eosin staining.

**Results:** It was found that the effect of nicotine after 24 hours with working solutions (10 $\mu$ M and 10mM) used on inflamed oral mucosal did not significantly affect on gross morphology.

**Conclusion:** The concentration of nicotine used after 24 hours did not affect tissue morphology.

**Keywords:** Tobacco, Nicotine, Epithelium, Oral mucosa, Morphology

## INTRODUCTION

The consumption of Tobacco is directly responsible for nearly 6 million deaths annually, and a further 600 000 people die each year from exposure to second-hand smoke.<sup>1</sup> Tobacco consumption is increasing globally, especially in developing countries, according to WHO statistical data.<sup>2</sup> The prevalence of smoking in countries like Western Europe, Australasia, and the United States and the developing world is rising.<sup>3</sup> People use different types of tobacco products which can be smoked, chewed or sniffed.<sup>4</sup> Products that are smoked such as Cigars, cigarettes, pipe tobacco and roll-your-own or

consumed Smokeless as chewing tobacco and snuff.<sup>5</sup> Cigarette smoking is a very popular habit and is associated with the development of cancers in humans.<sup>6</sup> The incidence of oral cancer is correlated with the use of tobacco products.<sup>7</sup> Oral cancer is considered as the 6th commonest cancer mostly affecting the male population of the world with a poor prognosis.<sup>8</sup> Cigarette smoking and tobacco use also play an important role in the development of other cancers in humans, including cancer of the esophagus, and the lungs.<sup>9</sup> Nicotine (C<sub>10</sub> H<sub>14</sub> N<sub>2</sub>) is an alkaloid, which only exists in tobacco plants called *Nicotina tabacum* present in the tobacco leaves and makes up about 5% of a tobacco plant by weight<sup>10</sup> and is highly addictive.<sup>11</sup> The side-effects associated with the smoking of Tobacco depends on a dose-response relationship to heavy smoking, and time duration.<sup>12</sup>

### Correspondence:

**Dr. Asmat Ullah**

Department of Oral Medicine, Khyber College of Dentistry,  
Peshawar, Pakistan.

Email: drasmatk@yaho.com

Contact: +923005930594

Tobacco also acts as the delivery system for the nicotine inside the body, and its use is harmful and dangerous from a health perspective.<sup>13</sup> It is now known that cigarette smoking is a result of addiction to nicotine, and the amount of nicotine taken up by the people who use Tobacco varies in each individual.<sup>14</sup> Nicotine is associated with a variety of lesions within the oral cavity.<sup>15</sup> It is suggested that nicotine might be related to the pathogenesis of oral white premalignant lesions.<sup>16</sup> Conditions and oral lesions associated with tobacco use include oral precancerous lesions such as leukoplakia, erythroplakia and smokeless tobacco keratosis and oral cancers such as squamous cell carcinoma and verrucous carcinoma.<sup>17</sup> Heavy consumption of Tobacco has also been associated with other lesions within the oral cavity such as tooth stains, abrasions, smoker's melanosis, acute necrotizing ulcerative gingivitis, burns and keratotic patches, nicotinic stomatitis, peri-implantitis and other periodontal conditions including increased plaque and calculus depositions, gingival recession and alveolar bone loss.<sup>18</sup> It is suggested that nicotine might be correlated to the pathogenesis of oral white lesions.<sup>19</sup> Carcinogens in tobacco smoke are associated with the developing of oral diseases and cancer. Nicotine adds to cancer etiology if it is nitrosated to form carcinogenic Tobacco specific nitrosamines.<sup>20</sup> In vitro studies have shown that when 0.216 M of nicotine is applied topically to the oral mucosa for two hours leads to alterations within the epithelium like acantholysis and nuclear shrinkage.<sup>21</sup> A study conducted by Chen et-al it was evident that when 6% nicotine alone or in a combination of other tobacco-specific nitrosamines such as 0.01% NNN, 0.01% NNK was applied on hamster cheek pouch and gastric mucosal epithelium, it revealed signs of hyperplasia, hyperkeratosis and also moderate dysplasia.<sup>22</sup> They concluded that these changes might be associated with the development of squamous cell papillomas in animals. Du et al. showed that nicotine is more rapidly and completely absorbed through the mucosal membrane of non-keratinized regions like the floor of the mouth that is the most permeable region, than through other parts of the mouth. Nicotine has also been shown to increase the permeability of oral mucosa to N-nitrosornicotine.<sup>23</sup> Therefore this study aimed to investigate the effect of nicotine on the morphology of an in vitro reconstituted model Of inflamed oral mucosa.

## MATERIALS AND METHODS

This observational laboratory study was conducted at Department of Oral Pathology, Barts, and London Queen Mary School of Medicine and Dentistry Queen Mary, University of London. The reconstituted human epithelium model used in the study was prepared and supplied by Skin Ethic Laboratories, Nice, France. The study focused on the effects of nicotine on an inflamed stratified epithelial layer when applied for 5 minutes and over 24 hours, respectively. The morphology of the stratified oral mucosal model was examined using formalin-fixed paraffin processed tissue. The reconstituted human epithelium is a three-dimensional tissue culture model derived from a buccal carcinoma and obtained by culturing transformed oral keratinocytes (TR146). The cells were seeded and cultivated in a specific medium for 14 days. The resulting culture came out to be a stratified epithelium with 5-7 cell layers of the epithelium (Fig 1). Model cultures were transferred into a new 24 well culture plates (Costar, UK) containing 500 $\mu$ l maintenance medium per well and incubated for 2 hours at 37°C in 5% CO<sub>2</sub> in a humidified atmosphere. The cultures were transferred to a new 24 well plate containing fresh media for all experiments. Working solutions: Concentrations of Nicotine and TNF- $\alpha$ : (10 $\mu$ M and 10mM) of nicotine were prepared from a 2.5M stock solution (Sigma, UK). The working solutions were diluted in phosphate-buffered saline immediately before use. TNF- $\alpha$  solution at (1000u/ml) were also prepared immediately before use. All solutions were discarded after each experiment. The morphology of the stratified oral mucosal model was examined using formalin-fixed paraffin processed tissue. The procedure was as follows:

At the end of the experiment, the inserts from nicotine treated and TNF- $\alpha$  stimulated was removed from the culture medium and rinsed in PBS. The culture was fixed by submerging in excess neutral buffered formalin for 24 hours at room temperature. The epithelium, with supporting polycarbonate membrane was dissected out of the inserts and the tissue processed to paraffin wax using an automatic tissue processor (Shandon Hyper centre II). 5 $\mu$ m sections were cut and stained with haematoxylin and eosin, examined by light microscopy while the image was recorded with digital photography.

## RESULT

To confirm the morphology results, the effect of 24 hours Nicotine with different treatments on tissue morphology was assessed using formalin-fixed paraffin wax sections and haematoxylin and eosin staining. All the samples of nicotine treated and TNF- $\alpha$  stimulated tissue were stratified with the presence of 10-15 epithelial layers and the absence of a stratum corneum (Figure 2-3), respectively. The results showed no evidence of damage or alteration to the surface layers or the basal layer of the stratified squamous epithelial models. In this experiment, tissue morphology was assessed by conventional light microscopy. Results from the application of nicotine after 24 hours treatment on TNF- $\alpha$  stimulated tissue, none of the treatments caused a significant effect on the morphological structure of the epithelium.

## DISCUSSION

This study aims to investigate the effect of nicotine on TNF- $\alpha$  stimulated reconstituted oral mucosa. The epithelial model allowed us to consider the effect of nicotine on an epithelial layer in the absence of any influence from mesenchyme. Stratified cultures were treated for 24 hours, respectively. Tissue morphology was assessed using formalin-fixed paraffin wax sections and haematoxylin and eosin staining. The results from morphology studies suggested that nicotine treatment of TNF- $\alpha$  stimulated reconstituted oral mucosa after 24 hours, respectively, had no significant effect on the morphological structure of the epithelium.

This was surprising as other studies have shown that nicotine has been shown to alter viability and morphology. In a previous *in vivo* study by Anderson and Warfving, revealed that nicotine exerted its biological effect on the oral mucosa and resulted in changes in the appearance of the epithelium.<sup>24</sup> Alpar et al., in their study, showed that 4mM nicotine dose caused significant morphological alterations of microtubules and vimentin filaments which then lead to atypical and vacuoles formation within the oral fibroblasts.<sup>25</sup>

Another similar type of study conducted on a reconstituted oral mucosa by Kwon et al. revealed that nicotine had no effect on the viability of the cells although decreased, dose-dependently, mucosal epithelial thickness at 10 $\mu$ M, and 100 $\mu$ M concentration,

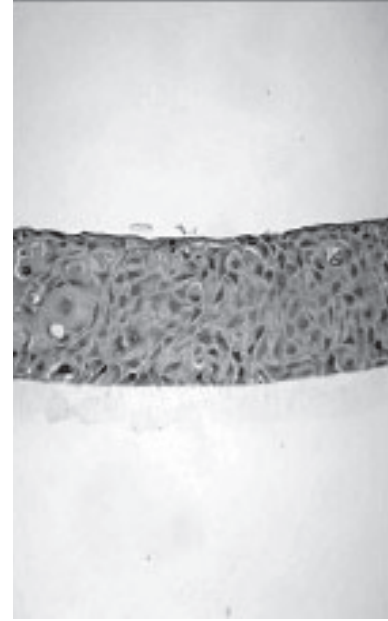


Figure 1. Haematoxylin and eosin-stained section of the mucosal model (original magnification x63)

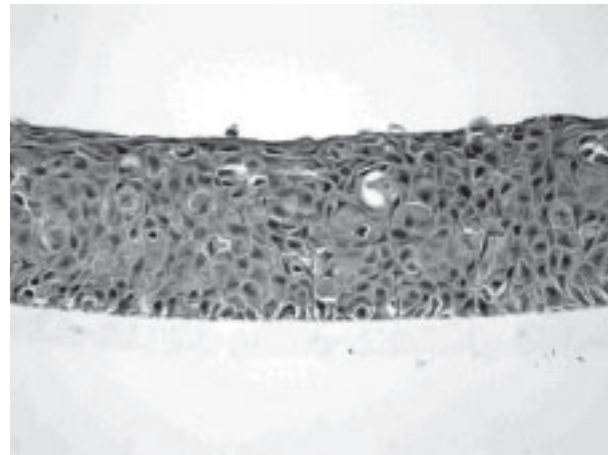


Figure 2. Haematoxylin and eosin-stained section of inflamed mucosa Treated with 10 $\mu$ M nicotine for 24 hours; original magnification x63

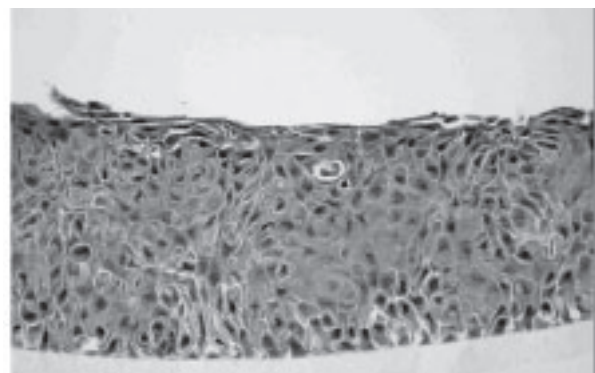


Figure 3. Haematoxylin and eosin-stained section of inflamed mucosa Treated with 10mM nicotine for 24 hours; original magnification x63

but nicotine reduced cell viability in the epidermal keratinocyte at a concentration 100µM.<sup>26</sup> Previously Alpar et al. had also linked higher doses of nicotine (10.5-15.5mM) to be responsible for causing irreversible changes in morphological appearance of the cells<sup>25</sup>. Squier and Johnson, also showed that when 0.2M nicotine was applied topically to the oral mucosa, after 2 hours, it induced acantholysis and nuclear shrinkage within the epithelium.<sup>27</sup> Further work could be required to confirm our observations. One simple variation would be to look at nicotine over a different range of concentrations. Different concentration may produce other effects on viability, cytokine release and morphology. As no change in morphology was seen in these experiments, it might be better to look for electron microscopic changes. For example, Squier and Johnson (1992) showed that nicotine leads to alterations within the epithelium like acantholysis and nuclear shrinkage.

## CONCLUSION

Nicotine concentration ranging from 10µM to 10mM had no significant effect on the morphology of the inflamed oral mucosa.

## REFERENCES

1. Low WY, Binns C. Tobacco consumption: the Asia-Pacific region's major public health problem. *Asia Pac J Public Health*. 2013;25:7S-9.
2. Ng M, Freeman MK, Fleming TD, Robinson M, Dwyer-Lindgren L, et al. Smoking prevalence and cigarette consumption in 187 countries, 1980-2012. *JAMA*. 2014;311:183-92.
3. Edwards R. ABC of smoking cessation: the problem of tobacco smoking. *BMJ: British Medical Journal*. 2004; 328(7433):217.
4. Amarasinghe H, et al. *Tob Control* 2018;27:542-546. DOI:10.1136/tobaccocontrol-2017-053791.
5. Ambrose JA, Barua RS. The pathophysiology of cigarette smoking and cardiovascular disease: an update. *Journal of the American college of cardiology*. 2004; 43(10):1731-7.
6. Martinez-Canut P, Lorea A, Magan R. 1996. Smoking and periodontal disease severity, *J. Clinical Perio* 22: 743-749.
7. Taybos, G., 2003. Oral changes associated with tobacco use. *Am J Med Sci*. 326:179-82.
8. Patel V, Leethanakul C, Gutkind JS. 2001. New approaches to the understanding of the molecular basis of oral cancer. *Crit Rev Oral Biol Med*.12:55-63.
9. Weisburger JH, Chung FL. 2002. Mechanisms of chronic disease causation by nutritional factors and tobacco products and their prevention by tea polyphenols. *Food Chem Toxicol*. 40 (8):1145-54.
10. Tomizawa M, Casida JE. Neonicotinoid insecticide toxicology: mechanisms of selective action. *Annu. Rev. Pharmacol. Toxicol.* 2005; 45:247-68..
11. Benowitz NL. Nicotine addiction. *New England Journal of Medicine*. 2010; 362(24):2295-303..
12. Mannino DM. Chronic obstructive pulmonary disease: definition and epidemiology. *Respir Care* 2003;48:1185-91, discussion 1191-3
13. Taybos G. Oral changes associated with tobacco use. *Am J Med Sci* 2003;326:179-82.
14. Jarvis MJ. ABC of smoking cessation: Why people smoke. *BMJ: British Medical Journal*. 2004; 328(7434):277
15. Taybos, G., 2003. Oral changes associated with tobacco use. *Am J Med Sci*. 326:179-82.
16. Kwon OS, Chung JH, Cho KH.1999. Nicotine enhanced epithelial differentiation in reconstructed human oral mucosa in vitro. *Skin Pharmacol Appl Skin Physiol* 12:227-234.
17. Sham AS, Cheung LK, Jin LJ, Corbet EF. The effects of tobacco use on oral health. *Hong Kong Med J* 2003;9:271-7.
18. Mirbod SM, Ahing SI. Tobacco-associated lesions of the oral cavity: Part I. Nonmalignant lesions. *J Can Dent Assoc* 2000;66:252-6.
19. Greer RO. Oral manifestations of smokeless tobacco use. *Otolaryngologic Clinics of North America*. 2011; 44(1):31-56.
20. Hecht SS. Tobacco carcinogens, their biomarkers and tobacco-induced cancer. *Nature reviews. Cancer*. 2003; 3(10):733.
21. Boffetta P, Hecht S, Gray N, Gupta P, Straif K. Smokeless tobacco and cancer. *The lancet oncology*. 2008; 9(7):667-75.
22. Cheng YA, Shiue LF, Yu HS, Hsieh TY, Tsai CC. Interleukin-8 secretion by cultured oral epidermoid carcinoma cells induced with nicotine and arecoline treatments. *The Kaohsiung journal of medical sciences*. 2000; 16(3):126-33..
23. Dussor, G. O, Leong SA, Gracia BN, Kilo S,† Theodore J. Price and Hargeaves KM et al. Potentiation of evoked calcitonin gene-related peptide release from oral mucosa: a potential basis for the pro-inflammatory effects of nicotine *Eur J Neurosci* 2010; 18 (9): 2515-26
24. Andersson G, Warfvinge G. The influence of pH and nicotine concentration in oral moist snuff on mucosal changes and salivary pH in Swedish snuff users. *Swed*

- Dent J. 2003;27(2):67-75.
25. Alpar B, Leyhausen G, Sapotnick A, Gunaay H, Geurtsen W. 1998. Nicotine-induced alterations in the human primary periodontal ligament and gingival fibroblast cultures. Clin Oral Invest. 2:40-6.
  26. Kwon OS, Chung JH, Cho KH.1999. Nicotine enhanced epithelial differentiation in reconstructed human oral mucosa in vitro. Skin Pharmacol Appl Skin Physio 12:227-234.
  27. Squier CA, Johnson GK.1992. Role of nicotine as a cofactor in smokeless tobacco carcinogenesis. Smoking and tob. Control Monograph 2: NIH pub 92: pp 153-160.