

PERCEPTION OF AESTHETICALLY PLEASING VERTICAL DISPLAY OF MAXILARY TEETH IN COMPLETE DENTURE IN POSED SMILE AMONG EDENTULOUS PATIENTS

Maria Qadeer¹, Ambreen², Mariya Khalid³, Sana Malik⁴, Nabila Khan⁵, Malka-e Noor⁶

¹Oral and Maxillofacial Surgery Department, Hayatabad Medical Complex (HMC) Peshawar, Paskitan

²Oral Pathology Department, Khyber Medical University (KMU) Peshawar, Paskitan

³Prosthodontics Department, Sardar Begum Dental College (SBDC), Peshawar, Paskitan

⁴Oral and Maxillofacial Surgery Department, Mardan Medical Complex (MMC) Peshawar, Paskitan

⁵Prosthodontics Department, Sardar Begum Dental College (SBDC), Peshawar, Paskitan

⁶Prosthodontics Department, Sardar Begum Dental College (SBDC), Peshawar, Paskitan

ABSTRACT

Objective: To determine the perception of aesthetically pleasing Vertical display of maxillary teeth of complete denture in posed smile among edentulous patients.

Materials and Methods: Fifty-three edentulous patients, age range 35 to 85 years, who visited department of Prosthodontics at Sardar Begum Dental College and Khyber College of Dentistry Peshawar to seek complete denture treatment, were included in this cross-sectional descriptive study. Picture of an edentulous patient wearing complete denture was modified using ADOBE PHOTOSHOP software. Six pictures with different vertical display of maxillary teeth were shown to edentulous patients and their perception was recorded in specially designed questionnaire.

Results: Out of 53 edentulous patients, 31 were males and 22 were females. Picture 5 (80% of vertical display of maxillary teeth) was selected as most attractive by 34% patients. The same picture was considered most natural by 16 (30.2 %) patients. Picture 1 (with no maxillary teeth display) was considered as most artificial by 52 (98.11 %) patients.

Conclusion: According to this study, the most appealing smile perceived by our edentulous population is when there is 80% of vertical display of maxillary teeth.

Keywords: Vertical display, Complete denture, Edentulous patients

INTRODUCTION

Esthetics means pertaining to the study of beauty and the sense of beautiful (GPT-9).¹ The word aesthetic originates from the Greek word "Aistheticos" which consist of two words. Aistheta=Perceptible things and Aisthesthai = Perceive².

Esthetics does not have a standard definition as it's the "Perception" which can be different among people of different regions and even individuals of the same region. Smile is one of the most beautiful

things that leaves a very good impression on others and is an important component of self-esteem of an individual.³ There are no standard parameters for esthetically pleasing smile as smile has different components and only when all components are in balance and also are according to norms of a society, only then, a smile is perceived to be beautiful.

In today's age, patients' demands and expectations have increased excessively regarding their dental appearance. With this change, dentists now face more challenges in satisfying patients and meeting their expectations. Increase in patients' expectations regarding their dental appearance has changed attitude of dentists too because now they have to do more thorough evaluation of smile by studying its different

Correspondence:

Dr. Maria Qadeer

BDS (SBDC), MCPS (HMC)

Email: drmaria1248@gmail.com

Contact: +923331966185

components and keeping them in balance according to a society.⁴ A natural smile consists of following parameters: smile line, curvature of upper lip, smile arc, labiodental relationship, amount of teeth display, symmetry, and gingival display, zenith positions of gingiva and position of incisal edges.⁵The desire to look young exists in all times and has increased even more in today's age. As the age increases, the incisal show decreases.⁶ Reduced incisal exposure is considered less esthetic as it gives more senile appearance.⁷ According to a study, the older an individual gets, younger he/she feels. When older adults were studied for their perceived age, they reported younger age as compared to their actual age.⁸ Giving reduced incisal show in complete dentures according to actual age of patient may not satisfy those patients who perceive themselves younger, as they will always desire to have a younger smile. There is a difference between spontaneous smile and posed smile. Spontaneous smile occurs naturally and is influenced by emotions whereas 'Posed smile' is the smile which occurs when an individual introduces himself/herself or at the time of taking photographs and is more repeatable and that's why taken as a reference in most of the studies.⁹

Up till now, no study has been conducted so far to evaluate perception of esthetically pleasing vertical teeth display in posed smile among edentulous patients. Keeping in mind desires of elderly population and increase in demand for youthful smile, there is a need to study adult edentulous patients regarding their perception of esthetically pleasing tooth display. The results of the study can be used as a guide for the clinicians to understand desires of the patient in a better way and take appropriate measures during teeth setup to meet patients' expectations.

OBJECTIVE

To determine the perception of aesthetically pleasing vertical tooth display of maxillary teeth in complete denture in posed smile among edentulous patients.

MATERIALS AND METHODS

A cross sectional (descriptive) study was conducted in department of Prosthodontics at Sardar Begum Dental College and Khyber College of Dentistry Peshawar, among edentulous patients who visited the department of Prosthodontics seeking

complete denture treatment. Sampling technique was non probability consecutive.

We included all edentulous patients, above 35 years age, visiting department of Prosthodontics at Sardar Begum Dental College and Khyber College of Dentistry Peshawar while Mentally handicapped patients and Patients with impaired eyesight were excluded. Study objectives were explained to them and informed consent was taken. Specially designed proforma was used for collection of data. To exclude bias from the study, the questions from all the patients were asked by same operator using pictures of same edentulous patient. Picture of an edentulous patient wearing complete denture was modified using ADOBE PHOTOSHOP software. In figure 1 patient has no maxillary teeth visible, in figure 2 patient has 20% vertical display of maxillary teeth, figure 3: 40% vertical display, figure 4: 50% vertical display, figure 5: 80% vertical display and in figure 6 whole length of maxillary teeth are visible. To test the face validity of the modified pictures, a questionnaire was made and was filled by 16 dentists after showing them the pictures. Out of them 13(81.25%) agreed. The data was collected and results obtained were analyzed using SPSS software version 16.0.

RESULTS

A total of 53 edentulous patients were enrolled in the study. Among them, 31 were males (58.49%) and 22 were females (41.50%). Their mean age was 54.72 SD \pm 1.514. Minimum age of the patients included in the study was 35 years and maximum was 85 years.

Among these 53 patients, 38 patients (71.7%) were illiterate, 10 patients (18.9%) had under secondary qualification and 5 patients (9.4%) were under graduate. 53 patients (100%) agreed that there is difference in appearance.

According to this study, Figure 5 (80% vertical display of maxillary teeth) was selected as most natural and most attractive, while appearance 1 (no maxillary teeth visible) was considered as most artificial.

Table 1: Patient perception regarding esthetically pleasing different verticle display of anterior teeth during posed smile

S.No	Most attractive	Most natural	Self-selection	Rank from least to most artificial
Appearance 1	0(0%)	1(1.9%)	0(0%)	1(1.9%)
Appearance 2	3(5.7%)	3(5.7%)	0(0%)	3(5.7%)
Appearance 3	15(28.3%)	14(26.4%)	14(26.4%)	10(18.9%)
Appearance 4	9(17.0%)	9(17.0%)	11(20.8%)	10(18.9%)
Appearance 5	18(34.0%)	16(30.2%)	19(35.8%)	20(37.7%)
Appearance 6	8(15.1%)	10(18.9%)	9(17.0%)	9(17.0%)

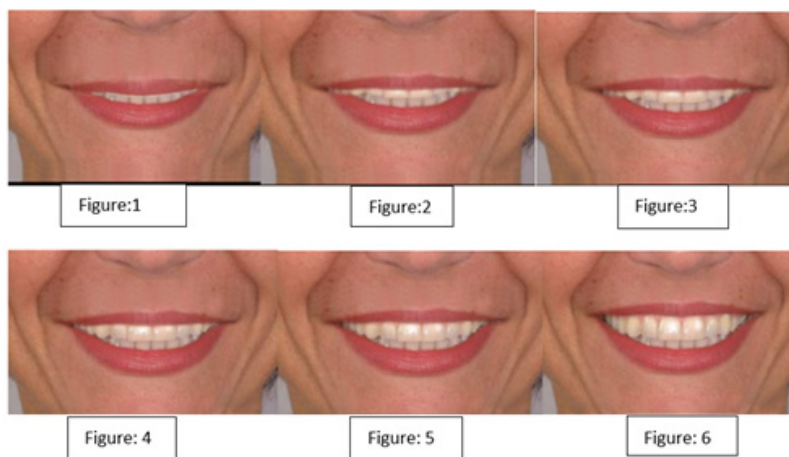


Figure: Patient with

- 1. No maxillary incisal show
- 2. 20 % incisal show
- 3. 40 % incisal show
- 4. 60 % incisal show
- 5. 80 % incisal show
- 6. Whole length of maxillary teeth visible.

DISCUSSION

Amount of teeth display is one of the key determinants in evaluation of smile esthetics and has a paramount importance on the psychology of patient¹⁰. Many studies are available which evaluated perception of dentate and young patients regarding their views about different components of smiles, however, studies on esthetically pleasing smile components of compete denture by edentulous patients are lacking.

In this study, 80 percent of the incisal show was considered most esthetically pleasing by the edentulous patients. This is in contrast with what is usually recommended for complete dentures. Direct comparisons are not possible as previously most of the studies have been conducted on esthetically pleasing incisal show/ incisocervical length of displayed teeth of dentate patients.

An individual’s evaluation of esthetics is affected by education level as well as social status.¹¹ This study was conducted in teaching hospitals where most of the patients belong to low or average socio-economic status so the results of the study can’t be generalized over entire population. According to this study, teeth display considered most attractive was the one in which 80 percent of the length of the teeth were visible. In a study conducted by Tosun H and Kaya B, smile considered attractive by orthodontists were when almost full crowns of maxillary teeth were visible whereas general dentist and laypersons were more tolerant of more coverage of maxillary teeth by lip. The smile attractiveness score decreases as the coverage of maxillary anterior teeth increases. These results are same as our study where smiles with reduced and absent incisal show were considered less attractive.¹²

A study conducted on “age related changes of

dental aesthetic zone at rest and during spontaneous smile and speech” showed that the maxillary lip line heights reduce significantly with increase in age.¹³ However, our population selected increased vertical incisor display despite the increased age. With the increase in esthetic demands, patients might not want to look as their chronological age and this seems to be the reason why increased incisal show was considered more attractive and was chosen as the smile which a patient wants for him/herself. Average maxillary incisal show in males is 1.91 mm and females are 3.40 mm. These measurements decrease with the increase in age.⁹ According to another study, females represent higher smile line whereas males represent average smile line.¹⁴ In the present study, picture of only female patient was used. This can be one of the reasons that increased vertical display was considered more appealing by most of the patients. While this clinical study gives valuable information regarding perception of edentulous patients, additional research is required to verify these findings with more advanced methods.

CONCLUSIONS

According to this study, the incisal show considered most appealing among our edentulous population is when 80 percent of the maxillary teeth are visible. The results of the study can be a useful guide for the clinicians to do teeth setup with increased tooth display especially for the patients demanding more youthful smile. Individual preference of tooth display can vary, so, it’s necessary not to proceed unless patient approves his tooth display at trial stage.

LIMITATIONS

Limitations of the study are as follows:

1. In this study, picture of only female edentulous patient wearing complete denture was used to determine perception of edentulous patients. Same study should be designed using pictures of male patient as well.
2. Another study should be conducted with larger sample size collected from different hospitals as well as private clinics so that patients belonging to different socioeconomic status can be included and findings of the study can be generalized on population more reliably.

REFERENCES

1. The Academy of Prosthodontics 2017, The glossary of prosthodontic terms-9th edition, Journal of Prosthetic dentistry, Vol:117, no: 5S, pp :1-105.
2. Glossary of literary and stylistic terms. Available at [<https://ignorik.ru/docs/unit-1-general-problems-of-stylistics.html?page=15>]
3. Gallego F, Larroulet C, Repetto A. What’s Behind Her Smile? Looks, Self-Esteem, and Labor Market Outcomes. 2018 Nov 15.
4. Sardar KP, Shahid A, Moiz A, Nadeem Y, Nayyar A. Perception of Smile by Orthodontists, Non-Dental and Dental Students: A Comparative Study. J Pak Dent Assoc 2017; 26(1): 1-5
5. Khan M, Kazmi SM, Khan FR, Samejo I. Analysis of different characteristics of smile. BDJ open. 2020 May 5;6(1):1-5.
6. Padmasree S, Bhanu Rekha S, Ranukumari A. Incisal Show–A Decrease with an Increase in Lines of Life. INTERNATIONAL JOURNAL OF SCIENTIFIC STUDY. 2016 Apr 1;4(1):213-7.
7. Jeelani W, Fida M, Shaikh A. The maxillary incisor display at rest: analysis of the underlying components. Dental press journal of orthodontics. 2018 Dec;23(6):48-55.
8. Chopik WJ, Bremner RH, Johnson DJ, Giasson HL. Age differences in age perceptions and developmental transitions. Frontiers in psychology. 2018 Feb 1;9:67.
9. Sabri R. The eight components of a balanced smile. J Clin Orthod. 2005 Mar 1;39(3):155-67.
10. Sriphadungporn C, Chamnannidiadha N. Perception of smile esthetics by laypeople of different ages. Progress in orthodontics. 2017 Dec;18(1):1-8.
11. Heravi F, Rashed R, Abachizadeh H. Esthetic preferences for the shape of anterior teeth in a posed smile. American Journal of Orthodontics and Dentofacial Orthopedics. 2011 Jun 1;139(6):806-14.
12. Tosun H, Kaya B. Effect of maxillary incisors, lower lip, and gingival display relationship on smile attractiveness. American Journal of Orthodontics and Dentofacial Orthopedics. 2020 Mar 1;157(3):340-7.
13. Van der Geld P, Oosterveld P, Kuijpers-Jagtman AM. Age-related changes of the dental aesthetic zone at rest and during spontaneous smiling and speech. The European Journal of Orthodontics. 2008 Aug 1;30(4):366-73.)
14. Nold SL, Horvath SD, Stampf S, Blatz MB. Analysis of select facial and dental esthetic parameters. Int J Periodontics Restorative Dent. 2014;34(5):623-9.)