

COMPARISON OF THE MEAN REDUCTION IN TRISMUS POSTOPERATIVELY AFTER USE OF 4MG AND 8MG INTRAVENOUS DEXAMETHASONE PRE OPERATIVELY, FOLLOWING IMPACTED MANDIBULAR THIRD MOLAR SURGERY

Ahmad Raza¹, Muhammad Younas², Nadia Ashraf¹, Abdul Wahid¹, Syed Amjad shah¹,
Muhammad Nisar³

¹ Department of Oral and maxillofacial surgery, Peshawar Dental College

² Department of Oral Medicine, Peshawar Dental College

³ Department of Oral Pathology, Peshawar Dental College

ABSTRACT

Objective: To compare the mean reduction in trismus postoperatively after the use of 4mg and 8mg intravenous dexamethasone preoperatively, following impacted mandibular third molar surgery.

Materials and Methods: This cross-sectional comparative study was conducted at the department of oral and maxillofacial surgery Peshawar dental college, Peshawar from 10th December 2018 to 16th July 2019 after the college's review board has approved it. In this study, a total of 60 Patients of both genders 18 years to 40 years with 35 mm or greater mouth opening, and partially impacted mandibular third molars were included by consecutive, non-probability sampling technique. The analysis of the data was done by using SPSS version 20.0. The student t-test was used to compare both groups i.e. mean reduction in trismus with 4mg dexamethasone and 8 mg dexamethasone on day 2. A $P \leq 0.05$ was taken as significant.

Results: After 2 days of administration of 4mg dexamethasone, the mouth was reduced from a mean of 49.63 ± 6.78 mm to 28.2 ± 2.917 mm. Similarly, after 2 days of administration of 8mg dexamethasone, the mouth was reduced from a mean of 50.3 ± 7.32 mm to 35.93 ± 2.50 mm. Genders have no effect on mouth opening after dexamethasone use. Age has an effect on the reduction of mouth opening after dexamethasone use. the mean reduction of maximum mouth opening (trismus) was less after giving 8 mg of dexamethasone than 4mg dexamethasone statistically significantly.

Conclusion: The use of 8 mg dexamethasone is found to be more effective in decreasing postoperative trismus in patient having third molar surgery as compare to 4mg dexamethasone.

Keywords: the Third molar; Impacted third molar, Trismus, And Dexamethasone

INTRODUCTION

The removal of the impacted mandibular third molar is one of the most common surgical procedures performed in the outpatient settings.¹

The prevalence of retained third molars in the

adult population is 80%.² A series of functional and structural alteration is expected after an extraction, mostly expressed as pain, swelling, trismus.² Lower impacted third molar surgical extraction usually causes complications such as dysaesthesia, severe infection, bone fracture, and dry socket.³ Impacted mandibular third molar is often associated with Pericoronitis, periodontitis, cystic lesion, neoplasms, pathologic root resorption and can cause unfavorable effects on neighboring tooth.⁴ Third molar removal causes some degree of pain and trismus, these ef-

Correspondence:

Dr. Ahmad Raza

Designation. Registrar, Department .Oral maxillofacial surgery College. Peshawar dental College.

Email: hmraza77@yahoo.com

Contact: :+923329279637

fects are originated from the synthesis and release of prostaglandins and other chemical pain mediators by the phospholipid membrane as a result of surgical trauma.⁵ Postoperative pain, swelling, trismus can be reduced via the membrane-stabilizing anti exudative effect of corticosteroid and by cyclooxygenase with an NSAID.⁶

Use of corticosteroid dexamethasone given as intramuscular, intravenously or submucosal either as preoperatively, perioperative or postoperative injection, appears to be effective in the prevention of postoperative oedema.⁷ Previously study shows that with the use of 4mg dexamethasone trismus

occurs up to 27.52 ± 3.42 mm and the use of 8mg dexamethasone trismus occurs up to 34.52 ± 8.04 mm in patients undergoing mandibular third molar surgery.⁴ Despite the frequent clinical use of dexamethasone, very few studies compare the use of different dosages.⁴

Grazini et al⁸ in his study reported swelling and pain after extraction of impacted third molar surgery. They use 10mg and 4mg dexamethasone sub mucosally before the surgery.⁵

Trismus, pain, swelling especially during the first post-operative week results in considerable difficulty in eating, speech, appearance, sleep and other daily activities. In pursuit of improved immediate postoperative patient quality of life after third molar surgery, there is a need to conduct clinical trials.⁵

The rationale of the study is to find out the postoperative effect of two different concentrations of 4mg and 8mg of intravenous dexamethasone on trismus.

MATERIALS AND METHODS

This cross-sectional comparative study was conducted at the department of oral and maxillo-facial surgery Peshawar dental college, Peshawar from 10th December 2018 to 16th July 2019 after the ethical committee has approved it. In this study, a total of 60 Patients of both genders 18 years to 40 years with 35 mm or greater mouth opening, and partially impacted mandibular third molars with class 2 or 3 occlusions and Pell and Gregory classification A, B, C in the radiograph were included by consecutive, non-probability sampling technique. A structured proforma was used to record the patient's demographic data like patient name, age, and gender.

Patients were divided into two groups by using the lottery method. In each group $n=30$ (50%), there was an equal number of patients. Group A was received 4mg dexamethasone intravenously one hour before the procedure.

Group B was received 8 mg dexamethasone intravenously one hour before the procedure. All the patients were advised to use a mouth wash chlorhexidine 0.2 % before given local anesthesia. After surgery, an NSAID like ibuprofen 400 mg; 1 tablet TDS for 4 days was prescribed. The outcome of both treatment modalities in terms of decrease in postoperative trismus at day 2 was measured. The analysis of the data was done by using SPSS version 20.0. Mean and the standard deviation was calculated for the quantitative variable like age and initial trismus. Frequencies and percentages were computed for categorical variables like gender. The student t-test was used to compare both groups i.e. mean reduction in trismus with 4mg dexamethasone and 8 mg dexamethasone on day 2. A $P \leq 0.05$ was taken as significant.

RESULTS

In this study, a total of 60 patients were included in which 32(53.2%) were males and 28(46.7%) were females. Thirty patients received 4mg dexamethasone and 30 patients received 8mg dexamethasone. The mean age was 28.78 ± 6.714 years. The age range was from 19 to 40 years. Most of the patients (36.7%) were presented in the age group 19-25 years followed by 36-40 years (26.7%).

the mean maximum mouth opening was 49.96 ± 7.005 mm, ranging from 38 to 61 mm preoperatively the removal of impacted third molar. Table 1 shows that the maximum mouth opening was almost similar before intervention (drug administration) in patients receiving two different dosages of dexamethasone. The difference was not significant ($P=0.716$).

After 2 days of administration of 4mg dexamethasone, the mouth was reduced from a mean of 49.63 ± 6.78 mm to 28.2 ± 2.917 mm as shown in

Table 2. This change in maximum mouth opening was statistically significant ($P=0.000$) as depicted in Table 3

Similarly, after 2 days of administration of 8mg dexamethasone, the mouth was reduced from a mean of 50.3 ± 7.32 mm to 35.93 ± 2.50 mm as shown in

Figure 1. This change in maximum mouth opening was statistically significant (P=0.000) as depicted in Figure 2.

The mean reduction in maximum mouth opening after giving 4 and 8 mg of dexamethasone in both genders was almost similar and was not statistically significant (P=0.78 for 4mg & 0.92 for 8mg). The details are given in Figure 3.

One way ANOVA test results showed that the mean reduction in maximum mouth opening stratified by age groups was statistically significant for both dosages of dexamethasone (P<0.05) as shown in Figure 5.

Figure 4 ,table 4 shows that the mean reduction of maximum mouth opening (trismus) was less after giving 8 mg of dexamethasone than 4mg dexamethasone statistically significantly (P<0.05).

DISCUSSION

Third molar surgery is one of the complications of the most common procedure that can always arise. The reported frequencies of complications after third molar removal are reported between 2.6 percent and 30.9 percent.⁹ The spectrum of complications ranges from minor expected sequelae of post-operative pain and swelling to permanent nerve damage, mandibular fractures, and life-threatening infections.^{10,11} In the current study we used consecutive sampling and there were 32(53.2%) males and 28(46.7%) were females. This shows that the males were more than females. This may due to the reason that more are outdoor working and financially independent. So have more chances to seek dental treatment especially surgeries.

In this study, the mean age was 28.78±6.714 years. The age range was from 19 to 40 years. The

Table 1: Preoperative maximum mouth opening in patients receiving two dosages of Dexamethasone

Drug	N	Minimum	Maximum	Mean	Std. Deviation*
4mg dexamethasone Preoperative maximum mouth opening	30	39.00	61.00	49.6333	6.78479
8mg dexamethasone Preoperative maximum mouth opening	30	38.00	61.00	50.3000	7.32097

Table 2: Maximum mouth opening before and after administration of 4 mg dexamethasone

Paired Samples Statistics				
Drug	Mean	N	Std. Deviation	Std. Error Mean
Preoperative maximum mouth opening	49.6333	30	6.78479	1.23873
Mouth opening after 2 days of injection	28.2000	30	2.91725	.53261

Table 3: Comparison of mouth opening before and after administration of 4mg dexamethasone

Paired Samples Test								
	Paired Differences					t	df	Sig. (2-tailed)
	Mean	Std. Deviation	Std. Error Mean	95% Confidence Interval of the Difference				
				Lower	Upper			
Preoperative maximum mouth opening - Mouth opening after 2 days of injection 4 mg	21.43333	7.97705	1.45640	18.45465	24.41201	14.717	29	.000

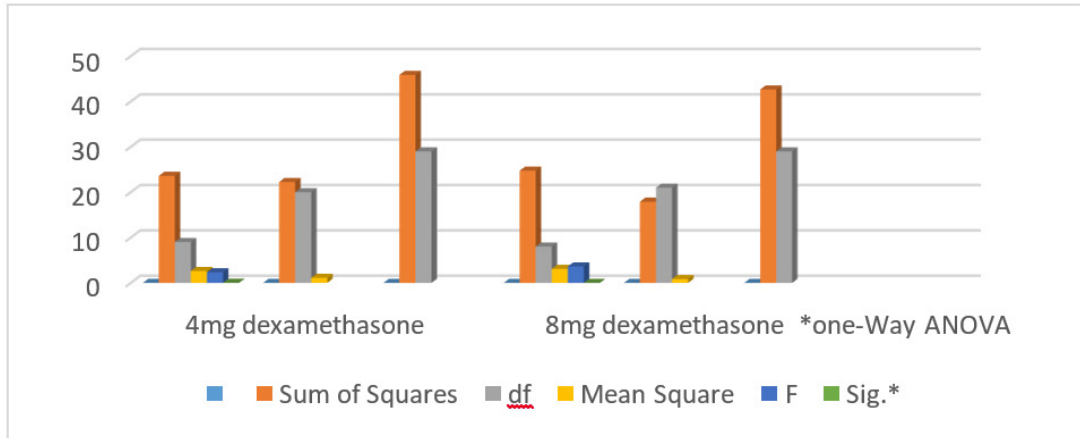


FIG 1: Preoperative and postoperative Maximum mouth opening after giving 8 mg dexamethasone

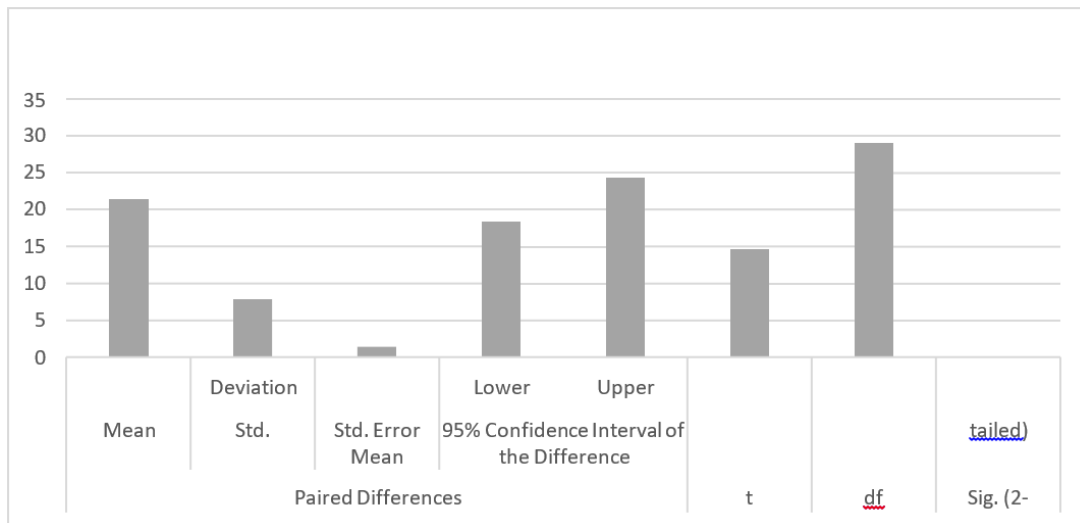


FIG 2: Comparison of mean reduction in mouth opening after two different dosages of dexamethasone stratified by age groups

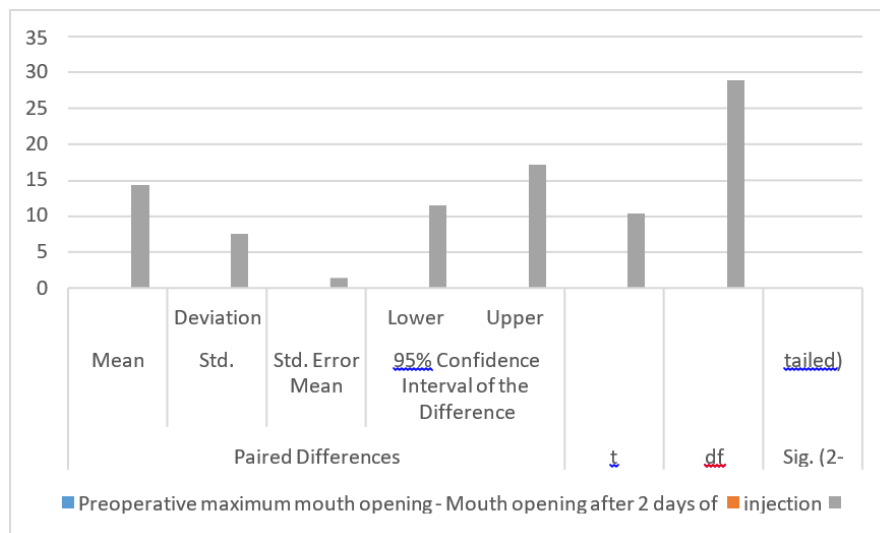


FIG 3: Comparison of mouth opening before and after administration of 4mg dexamethasone

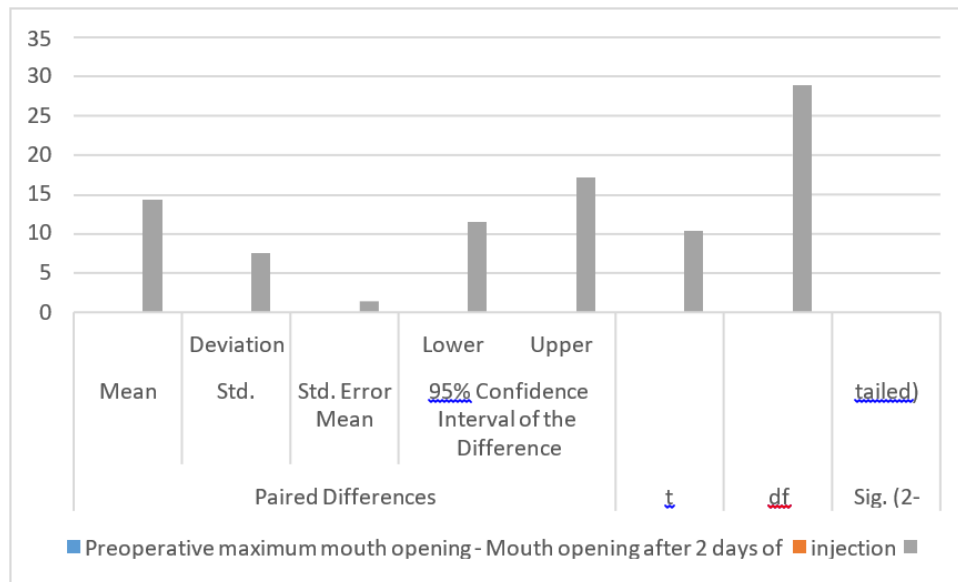


FIG 4: Comparison of mouth opening before and after administration of 8mg dexamethasone

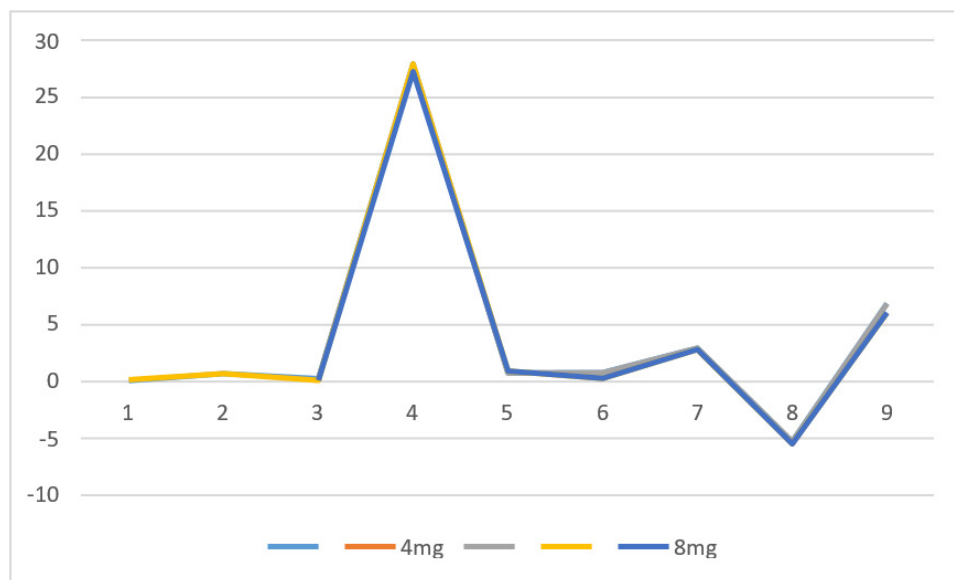


FIG 5: Comparison of mean reduction in mouth opening after two different dosages of dexamethasone stratified by genders

third molar usually erupts up to 18 years. After that, they are usually considered impacted. So in this study lower limit of age was 19 years. The upper limit was 40 years.

Molars are usually removed in symptomatic conditions like Pericoronitis etc. most of these appear before age.^{12, 13}

Schultze-Mosgau et al¹⁴ determined interincisal distance as an index of the trismus- reducing effects of the combination of non-steroidal anti-inflamma-

tory and corticosteroids. In the current study, we standard caliper to determine maximum interincisal distance.

The inflammatory process, the intensity or severity of postoperative sequelae such as pain, swelling and trismus may be reduced by drugs.¹⁵ use of steroid before the surgery decrease pain swelling and even there is decrease chances of limited mouth opening.¹⁶ most common steroid used in impacted third molar surgery are dexamethasone and methylprednisolone.

Table 4: Comparison of mean reduction of mouth opening after giving 4 versus 8 mg dexamethasone

Levene's Test for Equality of Variances	t-test for Equality of Means								
	F	Sig.	T	Df	Sig. (2-tailed)	Mean Difference	Std. Error Difference	95% Confidence Interval of the Difference	
								Lower	Upper
.144	.706	3.520	58	.001	7.06667	2.00755	3.04811	11.08522	
		3.520	57.840	.001	7.06667	2.00755	3.04788	11.08546	

Bierne and Holland¹⁷ use methylprednisolone in different dose in impacted third molar surgery.

125mg of methylprednisolone have no side effect

And patient have no pain and swelling post operatively

Result different from different study on the effectiveness of steroids in reduction of trismus after third molar surgery. Seward et al⁸ reported that steroids have no significant effect on trismus, Peterson et al¹⁹ support steroids use in impacted third molar surgery and concluded that it will help in minimizing post op pain, swelling and trismus. Literature revealed that before surgery use of intravenous dose of steroids had a major clinical impact on swelling and mouth opening in the early postoperative period. Miles and Desjardins.^{20,21} Ustun et al²² in there study compared the effects of two dosage of methylprednisolone 1.5mg/kg and 3.0mg/kg on pain, swelling and mouth opening after impacted third molar surgery and found no significant difference between the two doses. They supported low dosage of steroid is better to use because of their potential side effects.

In the current study, we used injectable dexamethasone to prevent postoperative trismus in impacted third molar surgery. Tiwana et al²³ compared recovery for clinical and health-related quality of life (HRQOL) outcomes after impacted third molar surgery in patients predicted to be at risk for delayed recovery, treated with or without intravenous (IV) steroids at the surgery. Clinical and HRQOL outcomes of these patients were compared with those of a non-concurrent control group who did not receive steroids. No antibiotics were given to patients. The control group was selected using the same criteria and treated under the same surgical protocol as the steroid group. They concluded that by giving pre-operative i/v steroids in mandibular impacted 3rd molar surgery without antibiotics does not affect

clinical recovery even when healthy adult patients are predicted to have delayed recovery. Overall, IV steroid administration had a limited, but beneficial effect on HRQOL outcomes.

In this study, before the extraction of the impacted third molar, the mean maximum mouth opening was 49.96 ± 7.005 mm, ranging from 38 to 61 mm. this the normal

Mouth opening documented in other studies as well. 88 So we only select having preoperative normal mouth opening.²⁴

In this study after 2 days of administration of 4mg dexamethasone, the mouth was reduced from a mean of 49.63 ± 6.78 mm to 28.2 ± 2.917 mm. This change in maximum mouth opening was statistically significant ($P=0.000$). Less than 35 mm is considered to be trismus. So in our study, most of the patients who were administered 4mg of dexamethasone injections were presented with trismus. Agostinho et al²⁵ conducted a study on Brazil's population to the efficacy of 2 different doses of dexamethasone to control postoperative swelling, trismus, and pain after third molar extractions. They reported that after 48hr of administration of 4mg i/v the mouth opening was 20 to 55 mm. these results are inconsistent with the current study.

In the current study after 2 days of administration of 8mg dexamethasone, the mouth was reduced from a mean of 50.3 ± 7.32 mm to 35.93 ± 2.50 mm and this change was statistically significant. Although the reduction in mouth opening was found after 8mg of dexamethasone it was above normal and cannot be considered trismus. Baxendale et al.²⁶ evaluated the effect of a single prophylactic dose of 8 mg oral dexamethasone on postoperative sequelae after mandibular third molar surgery in a randomized double-blind study of 50 adult patients. Dexamethasone resulted in a significant reduction

in pain 4 h postoperatively. The incidence of severe swelling was also reduced significantly, but there was no effect on trismus. The difference shows that oral 8mg dexamethasone is ineffective for controlling trismus. So injectable form of dexamethasone is recommended. Laureano Filho et al⁴ reported that the mean interincisal distance was 37.1±8.6mm after preoperative injection of 8mg dexamethasone. These results are inconsistent with our results.

Our results showed that 8mg i/v of dexamethasone preoperatively is more effective than 4mg of dexamethasone in controlling trismus. Laureano Filho et al⁴ investigated the effect of different concentrations (4 and 8 mg) of dexamethasone in a randomized clinical trial, comprising of 30 young individuals to reduce the postoperative swelling and trismus after the surgical removal of mandibular impacted 3rd molar. All the patients were given 4 mg and 8 mg of dexamethasone one hour before the surgical procedure. The selection of side to operate and the concentration of medication to be used was made randomly and double-blindly. Postsurgical pain was evaluated with the help of a visual analog scale (VAS) while the amount of swelling was checked through changes in the facial reference points. The degree of trismus was evaluated by measuring the interincisal distance (IID). All such measurements were obtained before the surgery and at 1st and 2nd postoperative day. They find out that the use of 8 mg of dexamethasone was more efficient as compare to 4mg in order to decrease both the degree of swelling as well as trismus. These results are in accordance to the current study.

CONCLUSIONS

The use of 8 mg dexamethasone is found to be more effective in decreasing postoperative trismus in patient having third molar surgery as compare to 4mg dexamethasone. It is recommended that such type of study should be performed on large sample size and in multiple centers to further evaluate the results in our community.

REFERENCES

1. Majid OW. Submucosal dexamethasone injection improves quality of life measures after third molar surgery: a comparative study. *J Oral Maxillofac Surg* 2011;69(9):2289- 97.
2. Kunkel M, Morbach T, Kleis W, Wagner W. Third molar complications requiring hospitalization. *Oral Surg Oral*

- Med Oral Pathol Oral Radiol Endod 2006;102(3):300-06.
3. Klongnoi B, Kaewpradub P, Boonsiririth K, Wongsirichat N. Effect of single dose preoperative intramuscular dexamethasone injection on lower impacted third molar surgery. *Int J Oral Maxillofac Surg* 2012;41(3):376- 79.
4. Laureano Filho JR, Maurette PE, Allais M, Cotinho M, Fernandes C. Clinical comparative study of the effectiveness of two dosages of dexamethasone to control postoperative swelling, trismus and pain after the surgical extraction of mandibular impacted third molars. *CEP* 2008;54753:220.
5. Antunes AA, Avelar RL, Neto ECM, Frota R, Dias E. Effect of two routes of administration of dexamethasone on pain, edema, and trismus in impacted lower third molar surgery. *Oral Maxillofac Surg* 2011;15(4):217-23.
6. Kang SH, Choi YS, Byun IY, Kim MK. Effect of preoperative prednisolone on clinical postoperative symptoms after surgical extractions of mandibular third molars. *Austr Dent J* 2010;55(4):462-67.
7. Dhanavelu P, Gapriyan S, Ebenezer V, Balakrishnan EM. Dexamethasone for third molar surgery—a review. *Int J Pharma and Bio Sciences* 2013;4(4):9-13. 68
8. Graziani F, D'aiuto F, Arduino P, Tonelli M, Gabriele M. Perioperative dexamethasone reduces post-surgical sequelae of wisdom tooth removal. A split-mouth randomized double-masked clinical trial. *Int J Oral Maxillofac Surg* 2006;35(3):241-46.
9. Bui CH, Seldin EB, Dodson TB. Types, frequencies, and risk factors for complications after third molar extraction. *J Oral Maxillofac Surg* 2003;61(12):1379-89.
10. Figueiredo R, Valmaseda-Castellón E, Berini- Aytés L, Gay-Escoda C. Delayed-onset infections after lower third molar extraction: a case-control study. *J Oral Maxillofac Surg* 2007;65(1):97-102.
11. Hupp JR, Tucker MR, Ellis E. Contemporary Oral and Maxillofacial Surgery-E-Book: Elsevier Health Sciences; 2013.
12. Rosen F, Milholland RJ. Mechanism of action of glucocorticoids. *Antineoplastic and Immunosuppressive Agents: Springer; 1975. p. 85-103*
13. Huggare J. Mosby's Dental Dictionary. *Eur J Orthod* 2015;37(2):230-30
14. Schultze-Mosgau S, Schmelzeisen R, Frölich J, Schmele H. Use of ibuprofen and methylprednisolone for the prevention of pain and swelling after removal of impacted third molars. *J Oral Maxillofac Surg* 1995;53(1):2-7.
15. Mense S. Sensitization of group IV muscle receptors to bradykinin by 5-hydroxytryptamine and prostaglandin E 2. *Brain Research* 1981;225(1):95-105
16. Skjelbred P, Løkken P. Post-operative pain and inflam-

- matory reaction reduced by injection of a corticosteroid. *Eur J Clin Pharmacol* 1982;21(5):391-96.
17. Beirne OR, Hollander B. The effect of methylprednisolone on pain, trismus, and swelling after removal of third molars. *Oral Surg Oral Med Oral Pathol* 1986;61(2):134-3818. Seward G, Harris M, McGowan D. An outline of oral surgery. Part one. Wright: Oxford; 1996.
 18. Peterson LJ, Ellis E, Hupp JR, Tucker MR. Contemporary oral and maxillofacial surgery: Mosby St. Louis, MO; 1988
 19. Milles M, Desjardins PJ. Reduction of postoperative facial swelling by low-dose methylprednisolone: an experimental study. *J Oral Maxillofac Surg* 1993;51(9):987-91.
 20. Hooley J, Francis F. Betamethasone in traumatic oral surgery. *J Oral Surg (American Dent Association: 1965)* 1969;27(6):398-403.
 21. Üstün Y, Erdoğan Ö, Esen E, Karsli ED. Comparison of the effects of 2 doses of methylprednisolone on pain, swelling, and trismus after third molar surgery. *Oral Surg Oral Med Oral Pathol Oral Radiol Endodont* 2003;96(5):535-3923.
 22. Tiwana PS, Foy SP, Shugars DA, et al. The impact of intravenous corticosteroids with third molar surgery in patients at high risk for delayed health-related quality of life and clinical recovery. *J Oral Maxillofac Surg* 2005;63(1):55-62
 23. Messer EJ, Keller JJ. The use of intraoral dexamethasone after extraction of mandibular third molars. *Oral Surg Oral Med Oral Pathol* 1975;40(5):594-98.
 24. Agostinho C, da Silva VC, Maia Filho EM, Cruz ML, Bastos EG. The efficacy of 2 different doses of dexamethasone to control post-operative swelling, trismus and pain after third molar extractions. *Gen Dent* 2014;62(6):1- 5.
 25. Baxendale B, Vater M, Lavery K. Dexamethasone reduces pain and swelling following extraction of third molar teeth. *Anaesthesia* 1993;48(11):961-64.
 26. Huffman G. Use of methylprednisolone sodium succinate to reduce postoperative edema after removal of impacted third molars. *J Oral Surg (American Dent Association: 1965)* 1977;35(3):198.
 27. Hargreaves KM, Costello A. Glucocorticoids suppress levels of immunoreactivity bradykinin in inflamed tissue as evaluated by microanalysis probes. *Clin Pharmacol Therapeut* 1990;48(2):168-78